



Disponible en ligne

<https://www.atrss.dz/ajhs>


Case Report

Association rare d'une Anorexie Mentale, Trouble Bipolaire et Trouble Obsessionnel Compulsif chez une adolescente

A rare case of association of Anorexia Nervosa, Bipolar Disorder and Obsessive Compulsive Disorder in a female adolescent

+* KADDOURI Sihem¹, + AOUAR Kenza¹, AOUADI Djihane^{1, 2}, NEDJARI Mohamed^{1, 2}

¹ University of Algiers Faculty of Medical Sciences, 02 Didouche Mourad St, Algiers, Algeria

² Drid Hocine Specialized Hospital Center of Psychiatry, 3 Mohamed Bonider St, Kouba, 16208, Algiers, Algeria

ABSTRACT

The association of Anorexia Nervosa (AN), Bipolar Disorder (BD), and Obsessive-Compulsive Disorder (OCD) is extremely rare. The objective of this paper is to highlight the complex therapeutic approach and rich clinical presentation of the combination of the three disorders.

We herein report a case of a 19 years old female adolescent with an unusual association of BD, OCD, and AN. The patient had several traumatic events in her childhood that contributed to the appearance of OCD, the first disorder. Later, the patient developed AN and BD. The patient made seven suicide attempts, the last one led her to our psychiatry care center. The patient was depressed with obsessional thoughts, and ritualistic behaviours, all of which met the Diagnostic and Statistical Manual of Mental Disorders, Fifth Edition (DSM-V) diagnostic criteria for AN, BD, and OCD. The wide range of treatment options available for the management of the three disorders separately showed to be insufficient to treat their association in our case.

This article reveals the complex clinical presentation and challenging medical management of the association of OCD, AN, and BD and encourages future research to investigate the common pathophysiological basis of the three conditions.

KEYWORDS: anorexia nervosa, bipolar disorder, obsessive-compulsive disorder, association, rare

RESUME

L'association de l'Anorexie mentale (AM), du Trouble Bipolaire (TB) et du Trouble Obsessionnel Compulsif (TOC) est extrêmement rare. L'objectif de notre article est de décrire la symptomatologie clinique riche et la prise en charge thérapeutique complexe qui caractérisent l'association des trois maladies.

Nous rapportons le cas d'une adolescente de 19 ans qui présente une association atypique de l'AM, TB et TOC. La patiente a vécu des événements traumatisants pendant l'enfance qui ont contribué à l'apparition du TOC, le premier trouble, suivi de l'AM et du TB. La patiente a commis sept tentatives de suicide dont la dernière a motivé son admission à notre niveau. La patiente était dépressive avec des idées obsessionnelles et comportement ritualisé. Les symptômes présentés par la patiente correspondent aux critères diagnostiques du Manuel diagnostique et statistique des troubles mentaux, cinquième édition (DSM-V) de l'AM, TB et le TOC.

Les traitements pharmacologiques recommandés pour la prise en charge de l'AM, le TB ou le TOC s'avèrent être insuffisants dans notre cas. Notre article encourage les recherches futures à investiguer les bases physiopathologiques communes aux trois maladies.

MOTS CLES: anorexie mentale, trouble bipolaire, trouble obsessionnel compulsif, association, rare



Introduction

Obsessive-Compulsive Disorder (OCD), Bipolar Disorder (BD), and Anorexia Nervosa (AN) are chronic psychiatric disorders that can cause serious behavioural, mood, and eating impairment respectively. Previous reviews showed that AN is highly comorbid with OCD (10-40%) [1], and less commonly with BD [2], but no simultaneous association of the three disorders has been reported.

The co-occurrence of the three disorders raises questions about possible common pathophysiological mechanisms, risk factors and potential treatment options.

Altered monoaminergic signalling, specifically the serotonergic and dopaminergic ones, is found in AN, OCD, and BD which may suggest the pathophysiological involvement of these systems in the genesis of the three diseases [3, 4, 5, 6, 7]. In addition, psychosocial risk factors, such as childhood trauma, have been commonly reported for the three conditions [8, 9, 10].

In terms of treatment options, Olanzapine is the most promising drug for patients with AN as studies have proved [11], whereas Serotonin Reuptake Inhibitors [12] and Cognitive-Behavioural Therapy [13] are both considered as first-line treatment of OCD. Selected atypical antipsychotics are largely used for the management of depressive episodes of BD instead of mood stabilizers [14]. For manic episodes, Risperidone, Olanzapine, and Haloperidol should be considered as among the best of the available options [15].

In addition to reporting a rare case of OCD, BD and AN association, this article aims to investigate possible beneficial effects of the combination of the different drugs used to treat the three disorders separately.

Case presentation

We report a case of a 19 year-old female who had suffered from school bullying for years and difficulty with building social relationships.

When she turned 13 years old, her childhood was disrupted by her father's incarceration, verbal/physical abuse in school against her escalated and her grades dropped profoundly. The patient developed increased

anxiety, insomnia, poor concentration and suicidal ideation.

After the release of her father, the patient started specific rituals such as organizing her books in a particular order and washing her body with bleach. The rituals were taking around 8 hours/day and caused marked anxiety.

Between 16 and 18 years old, the patient presented two episodes of psychomotor hyperactivity that lasted 3 months each and included: psychomotor agitation, high-uncontrolled energy and her sleep didn't exceed 2h. During the second episode (at age 17), the patient decided to adopt a healthier diet free from meat, sugar and pasta and ended up eating rice cake only with water.

From age 14 to today, the patient made 7 suicide attempts (one by defenestration, three by superficial phlebotomy, 2 by drug overdose and one by attempted hanging) that were all planned at least one week in advance.

In autumn 2020, the patient presented to our care center with complaints of suicide attempt by phlebotomy 5 days earlier, depressed mood, significant weight loss, fatigue and loss of energy, insomnia, loss of appetite, obsessional thoughts and ritualistic behaviours.

Mental examination revealed depressed patient with whom contact was possible but remained superficial. Her speech focused on three main ideas: the strong desire to die, the feeling of guiltiness towards her family and consistent beliefs of incurability; she repeated sentences such as "I've lost the taste of life, nothing makes me happy". Attention and concentration were sustained with good temporospatial orientation.

On admission, the patient was pale, short and thin with a body weight of 37,5kg (BMI=15kg/m²) and who could barely stand up. Physical examination revealed no abnormalities despite a three-week history of constipation. Complete blood count, lipid profile, renal function, and liver function tests were within normal limits. Beta HCG and COVID19 tests were negative.

The mental and physical examination findings met the DSM-V diagnostic criteria for AN, OCD, and BD, and the patient was hospitalized.

The patient scored 34 on the Hamilton Depression Rating Scale (severe depression), 22 on The Beck Scale for Suicide Ideation (strong intention), 38 on The Yale-Brown Obsessive Compulsive Scale (severe), 52 on the Eating Attitudes Test 26 (severe). The level of insight was 6 (bad insight).

At admission, the target weight was fixed at 45kg (BMI =18, 5 kg/m²). The patient was initially treated with Sertraline 100 mg/day, an initial dose of 50 mg /day of Quetiapine that escalated to 200 mg/day and Clorazepate 20 mg/day. After 10 days, the patient developed Quetiapine intoxication that required the immediate cessation of the treatment and her transfer to intensive care unit where she spent 24hours. The measurements taken were: rehydration, placement of a nasogastric tube for three weeks, therapeutic cessation, strict surveillance and blood test control after 10 days. Blood tests showed no abnormalities and the treatment was then re-initiated using different molecules: Olanzapine 10 mg/day, Fluoxetine 20 mg/day and Clorazepate 20 mg/day. The patient responded very well with noticeable mood improvement, she was discharged after two months of hospitalization and was prescribed the same previous treatment except for Fluoxetine (that was replaced by Escitalopram 10 mg/day) because of its relatively high manic switch rate. The patient reached the target weight of 45kg and began menstruating again after 2months. Her eating habits and negative thoughts remarkably improved (figure 1); OCD symptoms, however, persisted. Rapidly, the patient's state of health started declining again with significant weight loss and frequent major depressive episodes.

During the first 10 days of hospitalization, the patient was treated with Sertraline, Quetiapine and Clorazepate, her weight increased slightly and mood switched from major depression to hypomania. On the 11th day of hospitalization, the patient was admitted to the ICU after she presented Quetiapine intoxication. The treatment was then adjusted for the remaining days using Olanzapine, Fluoxetine and Clorazepate, the target weight was achieved progressively with remarkable mood improvement.

Discussion

To our Knowledge, the literature on the association of mood (BD) anxiety (OCD) and eating disorders (AN) refers almost exclusively to the association of two disorders but never to the three of them. Although no such association has been reported, some studies investigated possible common neuroimaging and genetic features between the three conditions. Evidence has shown a high genetic correlation between AN and OCD [16, 17] and other findings suggest genetic overlap between OCD and BD that needs to be further explored [18]. Several imaging techniques have been used to investigate brain changes in patients with OCD, AN or BD. The most altered common regions between the three conditions are frontal, temporal and limbic regions [19 – 27]. The above suggests that the association of OCD, AN and BD may respond to a somewhat similar set of interventions.

For our case, the three conditions presented by our patient overlap making the medical and psychological management challenging. On one hand, the patient has been experiencing frequent major depressive episodes with a decrease in appetite that worsens her AN symptoms. On the other hand, her obsessive behaviors have expanded to her eating habits: the patient feels the need to count her meal calories before eating and consistently checks her weight after. Such finding is consistent with recent studies that showed that obsessions seen in OCD was the most related cognitive-behavioral aspect to AN symptoms [28].

The childhood traumatic events experienced by the patient appear to play a major role in the development of OCD and AN. Her OCD symptoms started after her father's incarceration which negatively impacted the patient's mental health and led to chronic anxiety and feeling of danger. Her cleaning and organization compulsions were the primary symptoms of OCD and helped the patient control her fear and anxiety. In addition, she suffered from school bullying that caused deep low self-esteem and a negative body image.

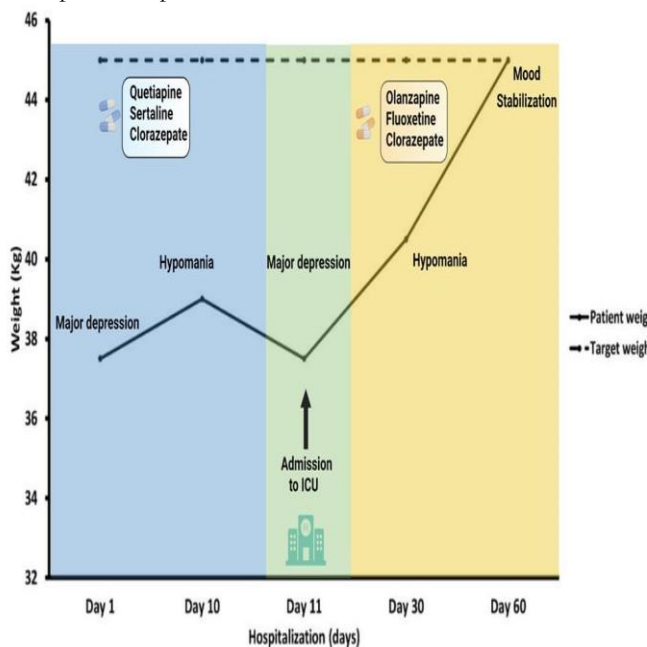


Figure 01 : Evolution of patient weight and mood during hospitalization

Throughout the years, the patient has developed a distorted perception of her own body, she feels today powerless and losing weight is a way for her to take back control. Both experiences endorse studies that emphasize the role of childhood traumatic events in the appearance of AN, OCD, and BD [8, 9, 10].

Unhealthy family dynamic is noticeable. The early symptoms presented by the patient, including suicide attempts, were considered by the parents as attention-seeking behaviors, such position was reinforced by socio-cultural beliefs and expectations. For our case, engaging the patient's parents in therapy is crucial.

The patient has a rapid cycling BD type 1 (more than 4 episodes per year) which confirms the severity of her disorder. In addition, her OCD symptoms slightly improved during her hospitalization. Clinical samples have demonstrated similar patterns: patients with AN and a family/personal history of BD tend to have numerous hospitalization, more suicide attempts and more psychiatric comorbidities [29] and patient with primary OCD and BD comorbidity showed greater severity of OCD measured by the Yale–Brown Obsessive Compulsive Scale (Y-BOCS) [30]. The patient underwent several treatment plan changes with poor clinical improvement showing the difficulties faced to find a suitable therapeutic association.

7. Conclusion

Our case report opens a debate about the nature of the relationship between BD, OCD, and AN whether it is causality or co-morbidity relationship, in other words, identifying whether there is a clear causal pathway between the three coexisting disorders or a mutual influence that increases the severity of each disorder. We encourage researchers to explore the nature of the relationship that exists between the three disorders.

8. Consent for publication

Written informed consent was obtained from the patient for publication of this case report and accompanying images.

9. Competing interests

The authors report no conflict of interest.

10. Funding

Not applicable.

11. References

1. Levinson, C. A., Zerwas, S. C., Brosof, L. C., Thornton, L. M., Strober, M., Pivarunas, B., Crowley, J. J., Yilmaz, Z., Berrettini, W. H., Brandt, H., Crawford, S., Fichter, M. M., Halmi, K. A., Johnson, C., Kaplan, A. S., La Via, M., Mitchell, J., Rotondo, A., Woodside, D. B., ... Bulik, C. M. (2019). Associations between Dimensions of Anorexia Nervosa and Obsessive-Compulsive Disorder: An Examination of Personality and Psychological Factors in Patients with Anorexia Nervosa. *European eating disorders review: the journal of the Eating Disorders Association*, 27(2), 161-172. <https://doi.org/10.1002/erv.2635>
2. Álvarez Ruiz, E. M., & Gutiérrez-Rojas, L. (2015). Comorbidity of bipolar disorder and eating disorders. *Revista de Psiquiatría y Salud Mental (English Edition)*, 8(4), 232-241. <https://doi.org/10.1016/j.rpsmen.2015.05.001>
3. Kaye, W. (2008). Neurobiology of Anorexia and Bulimia Nervosa Purdue Ingestive Behavior Research Center Symposium Influences on Eating and Body Weight over the Lifespan: Children and Adolescents. *Physiology & behavior*, 94(1), 121-135. <https://doi.org/10.1016/j.physbeh.2007.11.037>
4. MANJI, H. K., QUIROZ, J. A., PAYNE, J. L., SINGH, J., LOPES, B. P., VIEGAS, J. S., & ZARATE, C. A. (2003). The underlying neurobiology of bipolar disorder. *World Psychiatry*, 2(3), 136-146.
5. Frank, G. K., Bailer, U. F., Henry, S. E., Drevets, W., Meltzer, C. C., Price, J. C., Mathis, C. A., Wagner, A., Hoge, J., Ziolko, S., Barbarich-Marsteller, N., Weissfeld, L., & Kaye, W. H. (2005). Increased dopamine D2/D3 receptor binding after recovery from anorexia nervosa measured by positron emission tomography and [11c]raclopride. *Biological Psychiatry*, 58(11), 908-912. <https://doi.org/10.1016/j.biopsych.2005.05.003>
6. Nikolaus, S., Antke, C., Beu, M., & Müller, H.-W. (2010). Cortical GABA, striatal dopamine and midbrain serotonin as the key players in compulsive and anxiety disorders—Results from in vivo imaging studies. *Reviews in the Neurosciences*, 21(2), 119-139. <https://doi.org/10.1515/revneuro.2010.21.2.119>
7. Ashok, A. H., Marques, T. R., Jauhar, S., Nour, M. M., Goodwin, G. M., Young, A. H., & Howes, O. D. (2017). The dopamine hypothesis of bipolar affective disorder: The state of the art and implications for treatment. *Molecular Psychiatry*, 22(5), 666-679. <https://doi.org/10.1038/mp.2017.16>

8. Aas, M., Henry, C., Andreassen, O., Bellivier, F., Melle, I., & Etain, B. (2016). The role of childhood trauma in bipolar disorders. *International journal of bipolar disorders*, 4, 2. <https://doi.org/10.1186/s40345-015-0042-0>
9. Mathews, C. A., Kaur, N., & Stein, M. B. (2008). Childhood trauma and obsessive-compulsive symptoms. *Depression and Anxiety*, 25(9), 742-751. <https://doi.org/10.1002/da.20316>
10. Vanderlinden, J., & Palmisano, G. (2018). *Trauma and the eating disorders: The state of the art (chapter 2, pp 13-30)*. In A. Seubert & P. Virdi: *Trauma-informed Approaches to Eating Disorders*. (p. 13-30).
11. Attia, E., Steinglass, J. E., Walsh, B. T., Wang, Y., Wu, P., Schreyer, C., Wildes, J., Yilmaz, Z., Guarda, A. S., Kaplan, A. S., & Marcus, M. D. (2019). Olanzapine Versus Placebo in Adult Outpatients With Anorexia Nervosa: A Randomized Clinical Trial. *American Journal of Psychiatry*, 176(6), 449-456. <https://doi.org/10.1176/appi.ajp.2018.18101125>
12. Nazeer, A., Latif, F., Mondal, A., Azeem, M. W., & Greydanus, D. E. (2020). Obsessive-compulsive disorder in children and adolescents: Epidemiology, diagnosis and management. *Translational Pediatrics*, 9(S1), S76-S93. <https://doi.org/10.21037/tp.2019.10.02>
13. Simpson, H. B., Foa, E. B., Liebowitz, M. R., Huppert, J. D., Cahill, S., Maher, M. J., McLean, C. P., Bender, J., Marcus, S. M., Williams, M. T., Weaver, J., Vermes, D., Meter, P. E. V., Rodriguez, C. I., Powers, M., Pinto, A., Imms, P., Hahn, C. G., & Campeas, R. (2013). Cognitive-behavioral therapy vs risperidone for augmenting serotonin reuptake inhibitors in obsessive-compulsive disorder a randomized clinical trial. *JAMA Psychiatry*, 70(11), 1190-1198. <https://doi.org/10.1001/jamapsychiatry.2013.1932>
14. Post, R. M. (2016). Treatment of Bipolar Depression. *Psychiatric Clinics of North America*, 39(1), 11-33. <https://doi.org/10.1016/j.psc.2015.09.001>
15. Cipriani, A., Barbui, C., Salanti, G., Rendell, J., Brown, R., Stockton, S., Purgato, M., Spineli, L. M., Goodwin, G. M., & Geddes, J. R. (2011). Comparative efficacy and acceptability of antimanic drugs in acute mania: A multiple-treatments meta-analysis. *The Lancet*, 378(9799), 1306-1315. [https://doi.org/10.1016/S0140-6736\(11\)60873-8](https://doi.org/10.1016/S0140-6736(11)60873-8)
16. Cederlöf, M., Thornton, L. M., Baker, J., Lichtenstein, P., Larsson, H., Rück, C., Bulik, C. M., & Mataix-Cols, D. (2015). Etiological overlap between obsessive-compulsive disorder and anorexia nervosa: A longitudinal cohort, multigenerational family and twin study. *World Psychiatry*, 14(3), 333-338. <https://doi.org/10.1002/wps.20251>
17. Eating Disorders Working Group of the Psychiatric Genomics Consortium, Tourette Syndrome/Obsessive-Compulsive Disorder Working Group of the Psychiatric Genomics Consortium, Yilmaz, Z., Halvorsen, M., Bryois, J., Yu, D., Thornton, L. M., Zerwas, S., Micali, N., Moessner, R., Burton, C. L., Zai, G., Erdman, L., Kas, M. J., Arnold, P. D., Davis, L. K., Knowles, J. A., Breen, G., Scharf, J. M., Nestadt, G., ... Crowley, J. J. (2020). Examination of the shared genetic basis of anorexia nervosa and obsessive-compulsive disorder. *Molecular Psychiatry*, 25(9), 2036-2046. <https://doi.org/10.1038/s41380-018-0115-4>
18. Cederlöf, M., Lichtenstein, P., Larsson, H., Boman, M., Rück, C., Landén, M., & Mataix-Cols, D. (2015). Obsessive-Compulsive Disorder, Psychosis, and Bipolarity: A Longitudinal Cohort and Multigenerational Family Study. *Schizophrenia Bulletin*, 41(5), 1076-1083. <https://doi.org/10.1093/schbul/sbu169>
19. Frank, G. K., Shott, M. E., Hagman, J. O., & Mittal, V. A. (2013). Alterations in brain structures related to taste reward circuitry in ill and recovered anorexia nervosa and in bulimia nervosa. *The American Journal of Psychiatry*, 170(10), 1152-1160. <https://doi.org/10.1176/appi.ajp.2013.12101294>
20. Frank, G. K. W., Shott, M. E., Hagman, J. O., & Yang, T. T. (2013). Localized Brain Volume and White Matter Integrity Alterations in Adolescent Anorexia Nervosa. *Journal of the American Academy of Child and Adolescent Psychiatry*, 52(10), 1066-1075.e5. <https://doi.org/10.1016/j.jaac.2013.07.007>
21. de Wit, S. J., Alonso, P., Schweren, L., Mataix-Cols, D., Lochner, C., Menchón, J. M., Stein, D. J., Fouche, J.-P., Soriano-Mas, C., Sato, J. R., Hoexter, M. Q., Denys, D., Nakamae, T., Nishida, S., Kwon, J. S., Jang, J. H., Busatto, G. F., Cardoner, N., Cath, D. C., ... van den Heuvel, O. A. (2014). Multicenter voxel-based morphometry mega-analysis of structural brain scans in obsessive-compulsive disorder. *The American Journal of Psychiatry*, 171(3), 340-349. <https://doi.org/10.1176/appi.ajp.2013.13040574>
22. Hibar, D. P., Westlye, L. T., Doan, N. T., Jahanshad, N., Cheung, J. W., Ching, C. R. K., Versace, A., Bilderbeck, A. C., Uhlmann, A., Mwangi, B., Krämer, B., Overs, B., Hartberg, C. B., Abé, C., Dima, D., Grotegerd, D., Sprooten, E., Bøen, E., Jimenez, E., ... Andreassen, O. A. (2018). Cortical abnormalities in bipolar disorder: An MRI analysis of 6503 individuals from the ENIGMA Bipolar Disorder Working Group. *Molecular*

- Psychiatry*, 23(4), 932-942. <https://doi.org/10.1038/mp.2017.73>
23. Castro-Fornieles, J., Caldú, X., Andrés-Perpiñá, S., Lázaro, L., Bargalló, N., Falcón, C., Plana, M. T., & Junqué, C. (2010). A cross-sectional and follow-up functional MRI study with a working memory task in adolescent anorexia nervosa. *Neuropsychologia*, 48(14), 4111-4116. <https://doi.org/10.1016/j.neuropsychologia.2010.10.003>
 24. Thorsen, A. L., Hagland, P., Radua, J., Mataix-Cols, D., Kvale, G., Hansen, B., & van den Heuvel, O. A. (2018). Emotional Processing in Obsessive-Compulsive Disorder: A Systematic Review and Meta-analysis of 25 Functional Neuroimaging Studies. *Biological Psychiatry. Cognitive Neuroscience and Neuroimaging*, 3(6), 563-571. <https://doi.org/10.1016/j.bpsc.2018.01.009>
 25. Vocks, S., Herpertz, S., Rosenberger, C., Senf, W., & Gizewski, E. R. (2011). Effects of gustatory stimulation on brain activity during hunger and satiety in females with restricting-type anorexia nervosa: An fMRI study. *Journal of Psychiatric Research*, 45(3), 395-403. <https://doi.org/10.1016/j.jpsychires.2010.07.012>
 26. Wagner, A., Aizenstein, H., Venkatraman, V. K., Fudge, J., May, J. C., Mazurkewicz, L., Frank, G. K., Bailer, U. F., Fischer, L., Nguyen, V., Carter, C., Putnam, K., & Kaye, W. H. (2007). Altered reward processing in women recovered from anorexia nervosa. *The American Journal of Psychiatry*, 164(12), 1842-1849. <https://doi.org/10.1176/appi.ajp.2007.07040575>
 27. Bischoff-Grethe, A., McCurdy, D., Grenesko-Stevens, E., Irvine, L. E. Z., Wagner, A., Yau, W.-Y. W., Fennema-Notestine, C., Wierenga, C. E., Fudge, J. L., Delgado, M. R., & Kaye, W. H. (2013). Altered brain response to reward and punishment in adolescents with Anorexia nervosa. *Psychiatry Research*, 214(3), 331-340. <https://doi.org/10.1016/j.psychres.2013.07.004>
 28. Levinson, C. A., Brosnoff, L. C., Ram, S. S., Pruitt, A., Russell, S., & Lenze, E. J. (2019). Obsessions are strongly related to eating disorder symptoms in anorexia nervosa and atypical anorexia nervosa. *Eating Behaviors*, 34, 101298. <https://doi.org/10.1016/j.eatbeh.2019.05.001>
 29. M, V., L, R., J, D., F, C., & N, G. (2019). [Bipolar disorders and anorexia nervosa: A clinical study]. *L'Encephale*, 45(1). <https://doi.org/10.1016/j.encep.2017.10.005>
 30. Dell'Osso, B., Vismara, M., Benatti, B., Cirnigliaro, G., Grancini, B., Fineberg, N. A., Ameringen, M. V., Hollander, E., Stein, D. J., Menchon, J. M., Rodriguez, C. I., Nicolini, H., Lanzagorta, N., Pallanti, S., Grassi, G., Lochner, C., Marazziti, D., Hranov, G., Karamustafalioglu, O., ... Zohar, J. (2020). Lifetime bipolar disorder comorbidity and related clinical characteristics in patients with primary obsessive compulsive disorder: A report from the International College of Obsessive-Compulsive Spectrum Disorders (ICOCS). *CNS Spectrums*, 25(3), 419-425. <https://doi.org/10.1017/S1092852919001068>