



Disponible en ligne

<https://www.atrss.dz/ajhs>


Case Report

Troubles conductifs après administration de l'Hydroxychloroquine chez une patiente atteinte de l'infection COVID19

Cardiac conduction disorders after Hydroxychloroquine administration in patient with corona virus disease 19

ZOUZOU Hanane, MAHDJOUR Houria, ALLOUNE Imed

Université Batna

ABSTRACT

Corona virus disease 19 is a pandemic viral infectious disease; Some countries such as Algeria, have adopted therapeutic protocols including Hydroxychloroquine, the literature notes some cases of cardio toxicity.

Case report: We reported the case of 78-year-olds, female patient with corona virus disease 19 infection, referred to our center for cardiac conduction disorders, four days after Hydroxychloroquine treatment administration, she developed heart rhythm bradycardia, and surface electrocardiogram showed 2:1 atrio-ventricular block, with complete right bundle branch block for conducted P waves. Hydroxychloroquine was stopped immediately, Atropine administration was not efficient, and the patient refused insertion of temporary trans venous ventricular pacemaker.

After two weeks of hospitalization, his clinical status began improving, her electrocardiogram showed intermittent second degree Mobitz type 1 atrio ventricular block, and after three weeks, atrio ventricular block resolved completely but persistence of complete right bundle branch block.

Conclusion: Hydroxychloroquine may induce block in different level of cardiac conduction system, If Hydroxychloroquine administration is recommended, Continuous monitoring of cardiac rhythm is required, especially in elderly patients with past medical history.

KEYWORDS: Atrio-Ventricular Block, Right Bundle Branch Block, Corona Virus Disease 19, Hydroxychloroquine

RESUME

L'infection virale liée au coronavirus 19 est une pandémie. Certains pays comme l'Algérie ont adopté des protocoles thérapeutiques tels que l'hydroxychloroquine dont les effets sur le système cardiovasculaire sont divers, la littérature note certains cas de cardiotoxicité. Nous rapportons le cas d'une patiente âgée de 78 ans avec atteinte COVID 19, orientée vers notre centre pour des troubles de la conduction cardiaque, quatre jours après l'administration de l'hydroxychloroquine. Elle a développé une bradycardie sévère et l'électrocardiogramme de surface a montré un bloc auriculo-ventriculaire 2 pour 1, avec un bloc de branche droit complet pour les ondes P conduites. L'hydroxychloroquine a été arrêtée immédiatement, l'administration de l'Atropine n'était pas efficace et la patiente a refusé l'insertion d'une sonde de stimulation temporaire. Après deux semaines d'hospitalisation, son état clinique s'est amélioré, son électrocardiogramme a montré un bloc auriculaire ventriculaire 2^{ème} degré Mobitz 1 intermittent, et après trois semaines, le bloc auriculo ventriculaire a complètement régressé, mais le bloc de branche droit complet a persisté. L'hydroxychloroquine peut provoquer un blocage à différents niveaux du système de conduction cardiaque. Si l'administration d'hydroxychloroquine est recommandée, une surveillance continue du rythme cardiaque est nécessaire, en particulier chez les patients âgés ayant des antécédents médicaux.

MOTS CLES : Bloc auriculo-ventriculaire, bloc de branche droit, coronavirus 19, hydroxychloroquine



Introduction

Corona virus disease 19 is a pandemic viral infectious disease. First cases were recorded in China, in December 2019, and then spread globally all over the world. The disease was announced as pandemic by the World Health Organization in March 2020.

Some countries such as Algeria have adopted therapeutic protocols including Hydroxychloroquine. This drug was first developed for treatment and prophylaxis of malaria. Its effects on the cardiovascular system are diverse. Despite its anti-inflammatory effects and potential antithrombotic action, the literature notes some cases of cardio toxicity. Several degrees of cardiac conduction disturbances were reported in the setting of corona virus disease 19, but not related to Hydroxychloroquine.

Case report

We report the case of a 78 year-old female patient, with past medical history of hypertension on Irbesartan and Aspirin treatment, lower limb lymphoedema, and obesity (BMI: 50).

She initially presented fever, dry cough and shortness of breath. Because of pandemic COVID-19 infection, she was treated at home with Azithromycin (500 mg the first day, followed by 250 mg per day for four days), Vitamin C and Zinc.

Four days after starting treatment, she was hypoxic with an oxygen saturation of 75 % on room air, so she was admitted in the infectious disease department for more investigation and treatment.

Chest radiography revealed interstitial pulmonary syndrome (Figure 1). High-resolution chest computed tomography scan showed severe lung damage with multiple patchy ground glass opacities (GGO) (Figure 2). CT severity index of COVID-19 pulmonary infection was more than 50 %. She had inflammatory test abnormalities (elevated erythrocytes sedimentation rate: 100, C reactive protein: 24.43 mg/l, Fibrinogen 6.07g/l). High-sensitivity Troponin-T and electrolytes were within normal limits.

COVID-19 nasal swab reverse transcription polymerase chain reaction (RT-PCR) tested positive for the infection.

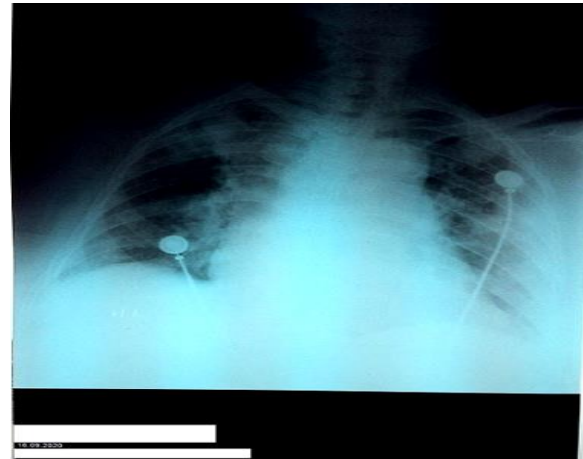


Figure 1: Chest radiography

On September 5, the diagnosis of COVID-19 infection has been maintained. ECG tracing performed before administration of Hydroxychloroquine (Plaquenil) treatment, showed normal sinus rhythm, with narrow QRS complexes; however, PR interval was 200 msec (Figure3).

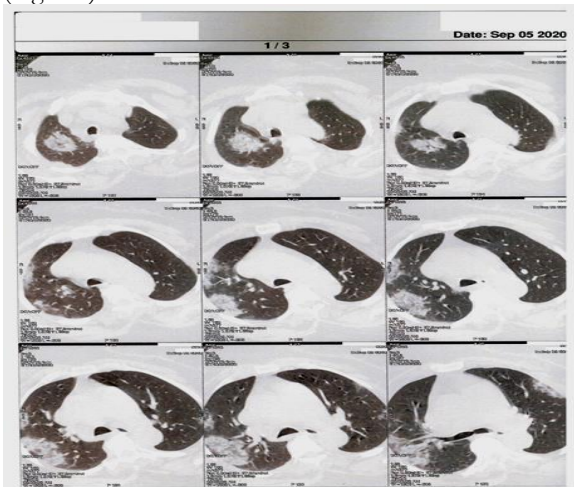


Figure 2: High-resolution chest computed tomography scan

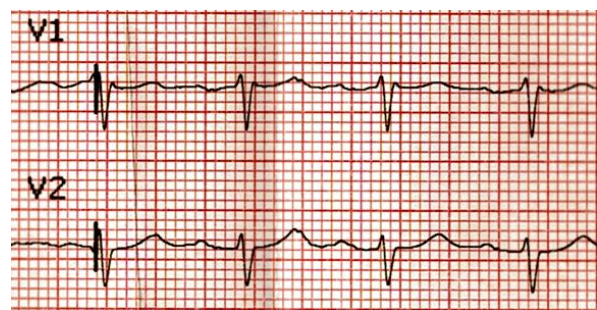

Figure 3: ECG before administration of Hydroxychloroquine treatment

In addition to oxygen therapy, Plaquenil (200 mg three times daily) was started on the fifth day (last day) of Azythromicin treatment. Therefore, there was a slight overlap between the two drugs.

Four days after Plaquenil administration, she developed heart rhythm bradycardia, and surface ECG showed 2/1 atrio-ventricular block (AVB) with complete right bundle branch block (RBBB) for conducted P waves (Figure 4). So, she was referred to our cardiology department on September 9 for therapeutic management. She was conscious, but presented dizziness.

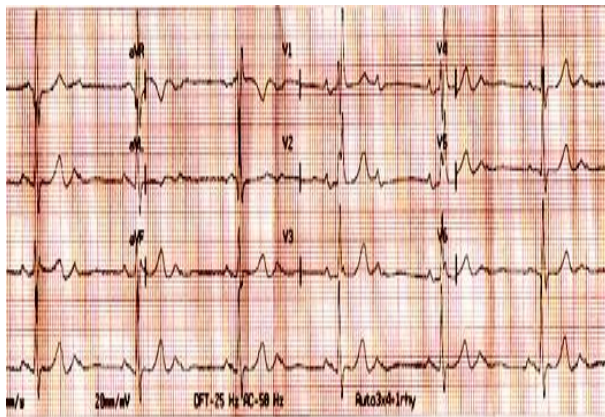


Figure 4: Surface ECG of patient four days after administration of Hydroxychloroquine treatment

Despite low echogenicity, her echocardiography showed normal left ventricular ejection fraction (Left ventricle ejection fraction about 58 %, with maximal velocity of tricuspid regurgitation less than 2.8 m/s) (Figure 5). Plaquenil was stopped immediately with continuous rhythm monitoring. Despite prescription of 0.25 mg of subcutaneous atropine every 6 hours, the rhythm has remained the same, so we stopped atropine administration. She also refused insertion of temporary trans venous ventricular pacemaker.

During hospitalization, serology tests for COVID 19 were positive (IgG > 40.62 AU/ml and IgM > 1.99 AU/ml).

On September 27, her clinical status began improving, her surface ECG showed intermittent second degree Mobitz type 1 AVB with persistent complete RBBB (Figures 6, 7, 8), so we concluded to nodal second degree AVB associated with complete RBBB. AVB resolved completely with persistent complete RBBB (Figure 9) and the patient was discharged from the hospital on October 5, 2020.

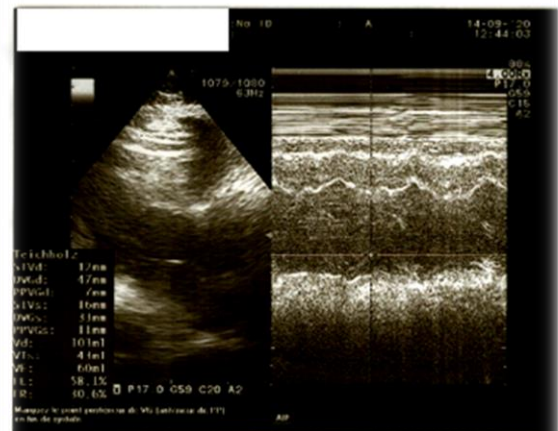
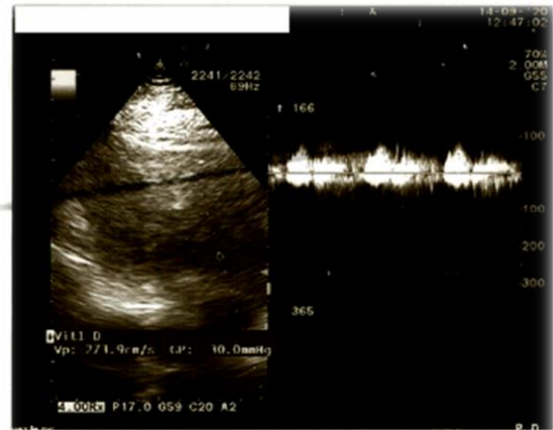


Figure 5: Echocardiography Doppler

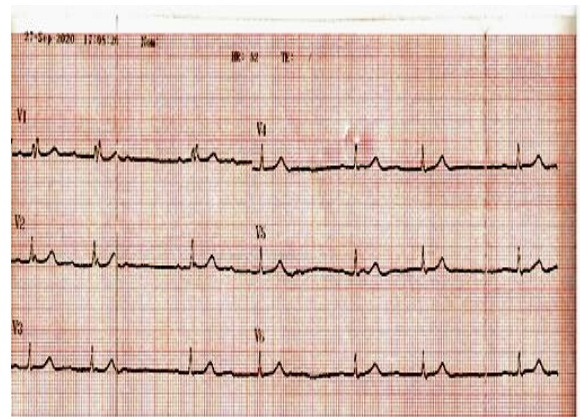

Figure 6: Surface ECG on September 27

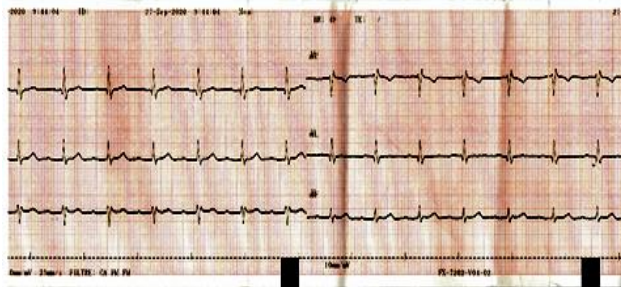


Figure 7: Surface ECG on September 27

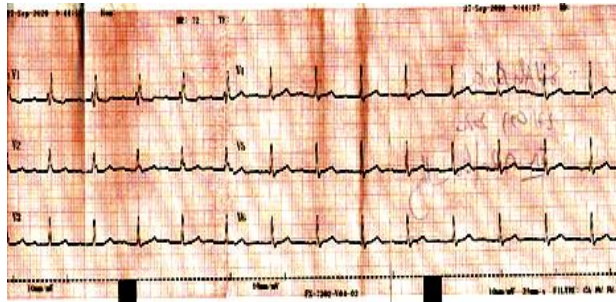


Figure 8: Surface ECG on September 27

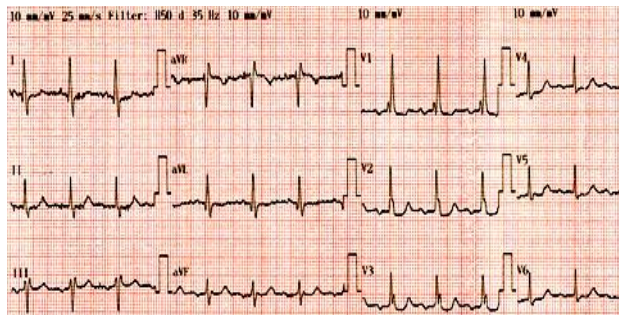


Figure 9: Surface ECG in the 5th of October

Discussion

COVID-19 is a pandemic viral infectious disease. First cases were recorded in China, in December 2019 [1] and then spread globally all over the world. The disease was announced as pandemic by the World Health Organization in March 2020.

It's caused by SARS-CoV (severe acute respiratory syndrome corona virus) and MERS (Middle East respiratory syndrome corona virus), that can cause severe respiratory disease in human.

Several organ damage have been reported in COVID-19 infection, including kidney failure, liver and heart injury, implying multiple organ involvement [2, 3, 4].

Cardiac damage has been reported in up to 19.7% of patients with COVID-19 [4, 5], arrhythmia has been noted in 16.7% of patients [6].

The new onset AV block, have been reported [7, 8, 9, 10] but the mechanisms are not clear.

In general population, the most common causes of AV block include degeneration of conduction system, infection, ischemia, inflammation, electrolytes abnormalities, and medications.

In the setting of SARS-CoV-2 infection, several causes are possible, such as hypoxemia, micro embolism, electrolytes abnormalities, drugs, and inflammatory surge from the cytokine storm or direct invasion of system conduction by COVID-19 virus, via Human angiotensin-converting enzyme 2 (ACE2) that provides a direct binding site for the S proteins of the SARS-CoV-2, and facilitates its cell entry [11].

Our patient has been on Irbesartan, an angiotensin receptor blocker with no effect on the cardiac conduction system; also neither Troponin elevation nor ventricular dysfunction was associated with second degree AV block, so we eliminated myocarditis or cardiac damage caused by corona virus.

In this patient, hypoxemia and inflammatory surge are unlikely causes of conduction disorders, because conduction disorders have appeared late and exactly 4 days after administration of Plaquenil.

Azithromycin is also known by its cardio toxicity and prolongation of QT interval, but second degree AVB with complete RBBB occurred three days after stopping this drug.

Second degree AVB and complete RBBB were not reversible after atropine administration; so enhanced vagal tone is unlikely cause of conduction disorders.

Plaquenil intoxication was the most likely cause of those conduction disorders, the second degree AVB was reversible, but complete RBBB persisted, this latter could be related to preexisting conduction disturbances revealed by Plaquenil administration.

The terminal half-life of Plaquenil ranges from 40 to 50 days which explains the progressive and delayed regression of those conduction disorders.

Chloroquine and hydroxychloroquine, were first developed for treatment and prophylaxis of malaria. These drugs were developed before modern drug safety surveillance programs. Their effects on the cardiovascular system are diverse, despite their anti-inflammatory effects and potential antithrombotic action, the literature notes some cases of cardio toxicity. Indeed, Chloroquine and hydroxychloroquine bind to cardiac sodium, calcium, and potassium channels (IKr) and cause QRS widening and conduction abnormalities [12]. They can also prolong the QT interval that could potentially initiate ventricular arrhythmias including torsades de pointes.

Conclusion

Cardiac conduction disorders during COVID-19 infection could be related to several mechanisms; in this case the most likely mechanism is

Hydroxychloroquine treatment, the second degree AVB was reversible, but not the complete RBBB which may also be related to preexisting conduction disorders. Hydroxychloroquine may induce block in different level of cardiac conduction system, if its administration is recommended, Continuous monitoring of cardiac rhythm is required, especially in elderly patients with past medical history.

Patient Consentement

Not applicable

Références

1. Wang D, Hu B, Hu C, et al. Clinical characteristics of 138 hospitalized patients with 2019 novel coronavirus-infected pneumonia in Wuhan, China. *JAMA* 2020; 323:1061–1069.
2. Cheng, Y.; Luo, R.; Wang, K.; Zhang, M.; Wang, Z.; Kidney impairment is associated with in-hospital death of COVID-19 patients. medRxiv 2020.
3. Guan, G.W.; Gao, L.; Wang, J.W.; Wen, X.J.; Exploring the mechanism of liver enzyme abnormalities in patients with novel coronavirus-infected pneumonia. *Chin. J. Hepatol.* 2020, 28, E002.
4. Shi S, Qin M, Shen B, et al. Association of cardiac injury with mortality in hospitalized patients with COVID-19 in Wuhan, China. *JAMA Cardiol* 2020; e200950.
5. Zhou F, Yu T, Du R, et al. Clinical course and risk factors for mortality of adult In patients with COVID-19 in Wuhan, China: a retrospective cohort study. *Lancet* 2020; 395: 1054–1062.
6. Zheng YY, Ma YT, Zhang JY, Xie X. COVID-19 and the cardiovascular system. *Nat Rev Cardiol* 2020; 17: 259–260.
7. Tala Eneizat Mahdawi, Haoyang Wang, Faris I. Haddadin, and all. Heart block in patients with coronavirus disease 2019: A case series of 3 patients infected with SARS-CoV-2
8. Faris I. Haddadin , Tala Eneizat Mahdawi, Laith Hattar and all A case of complete heart block in a COVID-19 infected patient *Journal of Cardiology Cases* 23 (2021) 27–30
9. Azarkish M, Laleh Far V, Eslami M, Mollazadeh R. Transient complete heart block in a patient with critical COVID-19. *Eur Heart J* 2020;41: 2131.
10. El Assaad I, Hood-Pishchany MI, Kheir J, Mistry K, Dixit A, Halyabar O, et al. Complete heart block, severe ventricular dysfunction and myocardial inflammation in a child with COVID-19 infection. *JACC Case Rep* 2020.
11. Yuefei Jin , Haiyan Yang , Wangquan Ji, Review Virology, Epidemiology, Pathogenesis, and Control of COVID-19. *Viruses* 2020, 12, 372.
12. Timothy J. Kamp, Mohamed H. Hamdan and Craig T. January, Chloroquine or Hydroxychloroquine for COVID-19: Is Cardiotoxicity a Concern? *Journal of the American Heart Association.* 2020;9:e 016887