

Rare association of a C1 C2 schwannoma in pregnant woman

About a case and literature review

Mouhamed f. , Mhacks m. , Abdou Aziz d. , Celebre m. , Seydou Boubacar B.

Fann hospital And department of Neurosurgery dakar main hospital SÉNÉGAL

ABSTRACT *Introduction* : Schwannomas are benign tumors of the nerve sheath of the Schwann cells present. Their intrachachideal cervical location is rare. The pregnancy schwannoma is poorly documented in the literature. Management is a real surgical challenge given the neurological and vital risk of the maternal fetus. *Material and methods*: 41-year-old CN patient with no specific history, 5 G 3 P 2 A, 3 weeks pregnant (Prolans test), who consulted the neurosurgical department for management of a balance disorder associated with paresthesia of the 4 limbs and a spinal rachialgia with a type of vice evolving for 2 years, in which the examination at the entry revealed a motor deficit of the 4 limbs to 4/5 with a tetra pyramidal syndrome. Cervical MRI revealed a heterogeneous lesion opposite C1-C2 of 31 mm / 21 mm right posterolateral compressing the cervical cord. Microsurgical excision by postero-median route with a C1-C2 laminectomy without arthrodesis. The postoperative follow-up was simple and then had a flexible cervical collar. The pathology examination returned in favor of a benign schwannoma. The evolution is marked by the persistence of paresthesia in the upper limbs with complete recovery from the complete motor deficit. Thus, a cesarean was performed at 38 weeks of pregnancy which gave birth to a female newborn weighing 2625 g with APGAR 8/10; 9/10; 10/10. *Conclusion* : Schwannomas gravidarum are rare C1 - C2 are peculiar compared to their counterparts in other regions of the spine in terms of their extradural and extra-spinal spread, relationships with neighboring structures and the surgical approaches necessary to cope. Although the clinical expression is variable, MRI and histology are the key diagnostic tests in their surgical management which must be carried out urgently given the risk of rapid tumor progression during pregnancy.

Keywords : *Fetal prognosis, Schwannoma C1-C2, Pregnant woman.*

INTRODUCTION

Schwannomas are benign tumors of the nerve sheath of Schwann cells present in the head and neck region in 25 to 45% of cases [1]. Spinal Schwannomas represent approximately 25% of vertebral tumors in adults with an incidence varying between 0.3 and 0.4 cases / 100,000 people [5]. The association of a schwannoma with pregnancy is rare and poorly documented, its management is a real surgical challenge given the neurological and vital risk of the maternal fetus.

OBSERVATION

41-year-old CN patient with no specific history, 5 G 3 P 2 A, 3 weeks pregnant (Prolans test), who consulted the neurosurgical department for management of a balance disorder associated with paresthesia of the 4 limbs and a dorsal rachialgia

with a type of vice evolving for 2 years, in which the examination at the entry revealed a motor deficit of the 4 limbs 4/5 with a tetra pyramidal syndrome. Cervical MRI revealed a lesion opposite C1-C2, strongly gadolinium of 31 mm / 21 mm right posterolateral compressing the cervical cord and increasing g. Microsurgical excision by postero-median route with a C1-C2 laminectomy without arthrodesis. The postoperative follow-up was simple and then had a flexible cervical collar. The pathology examination returned in favor of a benign schwannoma. The evolution is marked by the persistence of paresthesia in the upper limbs with complete recovery from the complete motor deficit. Thus, a cesarean was performed at 38 weeks of pregnancy which gave birth to a female newborn weighing 2625 g with APGAR 8/10; 9/10; 10/10

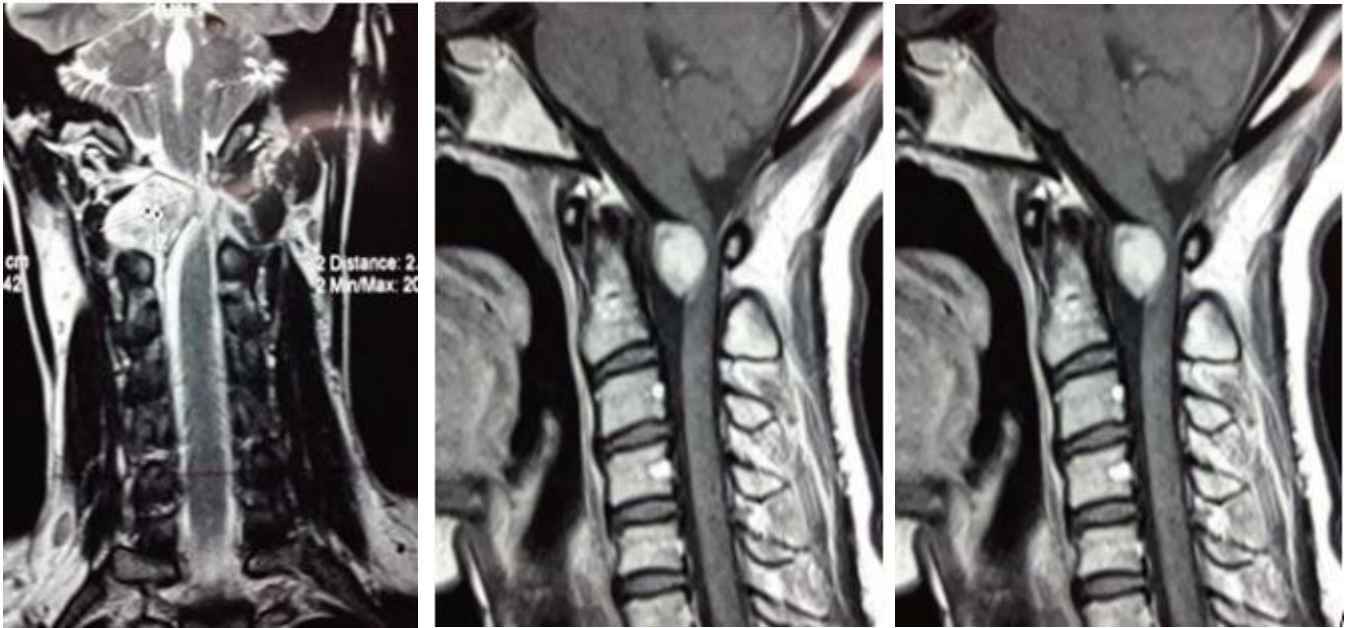

fig 1. cervical preoperative MRI : heterogeneous lesion opposite c1-c2 compressing the cord (T1 and T2 gado)

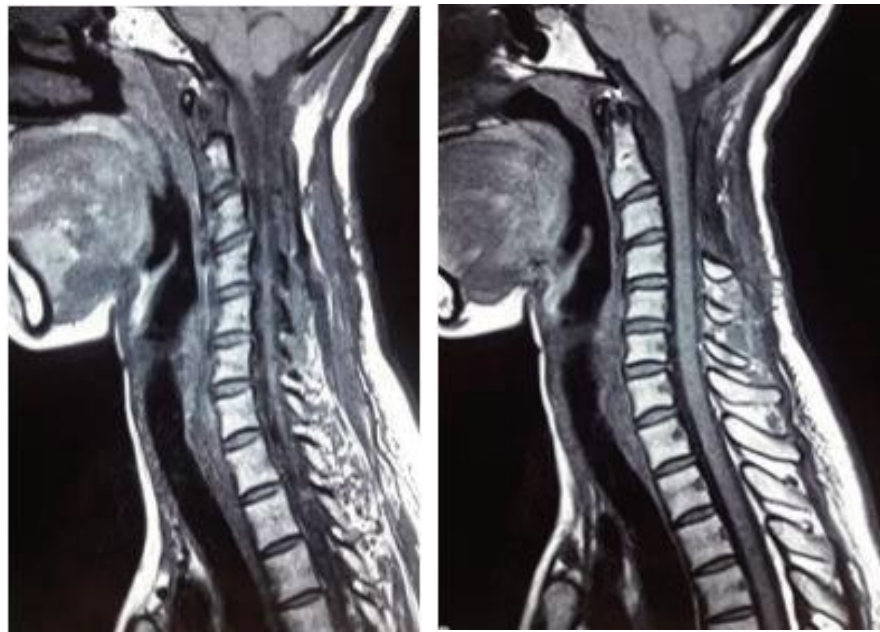


fig 2. Postoperative cervical MRI at 8 months postoperative:presence of intramedullary area oppositec2, in t2 hyper signal, t2 fast sAt, in iso t1 signal not enhanced after injection of contrast product in favor of a sequellar lesion.

DISCUSSION

Spinal Schwannomas are common spinal tumors and represent about 25% of intradural tumors of the spinal cord in adults [5]. Upper cervical localization is rare. [1 - 5, 8,10]

A schwannoma in pregnant women is rare, our diagnosis was made in the first trimester unlike most authors in the literature, notably Tong and all in 2015 who found 3 cases (including a

cervical location C3-C4, a dorsal and one lumbar) on 21 spinal tumors associated with pregnancy and in which the diagnosis was made rather in the second and third trimesters [10]. Certain factors, including the strong expression of progesterone receptors and glucocorticoids of schwannoma, intra tumor tumoral vascularity, edema, spontaneous hemorrhage, tumor necrosis, immune invasion of these antigens could lead to tumor growth rapid during Pregnancy [3].

Considering the available data and the risk of teratogenicity, the American College of Radiology concludes that no special consideration is recommended for the first trimester compared to any other trimester of pregnancy [8].

MRI is the reference examination, in our case we found a lesion opposite C1-C2 of 31 mm / 21 mm right posterolateral, this localization is extremely rare unlike that found in the literature, especially in T9 - T10; L1; S1; C3 - C4 and T 7 [2; 3].

The medical complex, ethical, psychological and religious problems occurring in pregnant women require a multidisciplinary care (a team of obstetricians, oncologists, radiation oncologists, surgeons, pediatricians, geneticists, psychologists, teratologists and clinical pharmacologists). Obviously, maternal health is the main priority. Consequently, the proposed treatment must respect the standard treatment for non-pregnant women [7]. Despite the multiple surgical approaches proposed in the literature (posterior, posterolateral, lateral and anterolateral), tumor excision of the upper cervical spine is in itself a real surgical challenge and the posterior median route remains the most used in most literatures. [1 - 3]. This corroborates what was done with our patient (a microsurgical excision without arthrodesis). No pre or postoperative complication was reported in our series, unlike some found in some literature, including instability or vertebral deformation [1] or meningoceles [6] or LCS leakage and clinical progress is marked by motor recovery and persistence of paresthesias of the 4 limbs. Although no instability was noted, long-term follow-up is advised for this problem. But if instability is present, it should be stabilized immediately [1].

CONCLUSION

Schwannomas of the upper cervical spine are rare and their association with pregnancy is their surgical management is multidisciplinary with adequate surgical timing definition (rapid tumor evolution during pregnancy). Although clinical expression is variable, MRI and histology are key

diagnostic tests in their surgical management. Only a handful of reports exist in the literature on spine surgery during pregnancy. 56% of women would have low back pain during gestation. Similar to intracranial tumors, preexisting vertebral tumors can show accelerated growth and become symptomatic during pregnancy. (9).

Conflict of interest: No potential conflicts of interest related to this article have been reported.

REFERENCE

- 1] RUQIA ASNA RABAH1, SHAKEEL AHMED KHAN2, KHUDSIA FATIMA, MM BAIG, An amazing case report of cervical Schwannoma, 2014.
- 2] RUIQI CHEN, ANQI XIAO, LU XING, A rare thoracic intra spinal Schwannoma in twin Pregnancy with aggravated clinical presence, A case report following care, 2015.
- 3] CHOWDHURY FH, HAQUE MR, Giant invasive spinal Schwannomas: definition and surgical management, Sridhar K, Ramamurthi R, Vasudevan MC, High cervical spinal Schwannoma; Microneurosurgical management: an experience of 15 cases, 2001.
- 4] JOE M. DAS, ANILKUMAR PEETHAMBARAN, Total Excision of a Giant Ventral Midline Cervical Spinal Intradural Schwannomas via Posterior Approach, Asian Spine J 2016; 10 [1]: 153-157
- 5] YOUSOUF SOGOBA1, BOUBACAR SOGOBA1, DRISSA KANIKOMO, SEYBOU HASSANE DIALLO, DJENÈ KOUROUMA1, OUMAR COULIBALY, ISSA AMADOU4, MOUSTAPHA MANGANÉ, HAMIDOU ALMEIMOUNE5, MADANI THIerno DIOP5, YOUSOUFA MAIGA2, BROULAYE SAMINAL, GABRIEL TOURÉ Hospital: Review of 11 Cases, Bamako, Mali, 2018.
- 6] JOE M. DAS, ANILKUMAR PEETHAMBARAN, Total Excision of a Giant Ventral Midline Cervical Spinal Intradural Schwannomas via Posterior Approach, Asian Spine J 2016; 10 [1]: 153-157

-
- 7] FRÉDÉRIC AMANT, MD, PHD, PROFESSOR, GYNECOLOGICAL ONCOLOGIST A, SILENY N. HAN, MD, PHD, Fellow in Gynecological Oncology a, Mina Mhallem Gziri, MD, PhD, Obstetrician b, Tineke Vandebroucke, MSc, Psychologist, PhD Fellow a, Magali Verheecke, MD, PhD, Fellow in Gynecological Oncology a, Kristel Van Calsteren, MD, PhD, Professor, Obstetrician, Management of cancer in pregnancy, Gynecologic Oncology, University Hospitals Leuven, Division of Oncology, KU Leuven, Leuven, Belgium , 2015.
- 8] Committee on Obstetric Practice, the American College of Radiology and the American Institute of Ultrasound in Medicine Guidelines for Diagnostic Imaging During Pregnancy and Lactation, ACOG COMMITTEE OPINION Number 723, USA, October 2017.
- 9] LT COL SHALENDRA SINGH A, MAJ GEN NAVDEEP SETHI BA Assistant Professor, Neuroanesthesia and pregnancy: Uncharted waters, Department of Anaesthesiology & Critical Care, Armed Forces Medical College, Pune 411040, India b Commandant, Command Hospital (Southern Command), Pune 411040, India, 2015.
- 10] TONG MENG, MD, HUABIN YIN, MD, ZHENXI LI, MD, BO LI, MD, WANG ZHOU, MD, JING WANG, MD, LEI ZHOU, MD, Dianwen Song, MD, and Jianru Xiao, MD Therapeutic Strategy and Outcome of Spine Tumors in Pregnancy A Report of 21 Cases and Literature Review, SPINE Volume 40, Number 3, pp E146 - E153,2015, China.