

---

## CYSTIC MENINGIOMAS REPORT OF FOUR CASES

M. BOUALLAG, N. BOUZID, F. BOUATTA, S. ZENINI,  
L. GUENANE, B. ABDENNEBI

*Department of Neurosurgery,  
Salim Zemirli Algiers, Algeria*

---

**ABSTRACT :** Although intra cranial meningiomas are usually solid tumors, some are associated with confusing cysts. So, computed tomography scan and conventional magnetic resonance imaging may not easily differentiate these lesions from other tumors frequently associated with cystic or necrotic component as gliomas or metastasis. We report four cases of cystic meningioma in which the diagnosis was not suspected preoperatively because of short clinical history and rapid neurological deterioration. However, a cystic component on imaging studies confused the diagnosis of meningioma with other cyst lesions. Although some authors report that hemorrhage is rare in meningioma, one of our cases was associated with hemorrhage and was histologically grade I meningioma. Total removal of cystic meningioma was our goal and histopathological examination was important to establish the diagnosis after surgery.

**Key words :** *Meningioma, Cystic meningioma, Cystic tumours.*

---

### INTRODUCTION

Cystic meningiomas are rare benign lesions. They represent 2-4% of all intracranial meningiomas.

Diagnosis is difficult because they can lead to confusion with other cystic lesions such as cystic astrocytoma or hemangioblastoma.

The diagnosis is rectified by pathological examination.

We report four cases of cystic meningiomas whose diagnosis was confirmed by histological study.

### CASE 1

A 25 years old woman, without previous disease, presented during the 7th month of pregnancy, psychiatric disorders such as depression (isolation, phobia and dark thoughts), insomnia and anxiety state. These signs worsened in postpartum followed twenty days later by tonico-clonic seizures (2 to 3 seizures/day) and intense headache refractory to conventional analgesics. Medical treatment with antidepressants and antiepileptic was instituted followed by radiological examination (cerebral CT scan and MRI).

Presenting symptoms were a high intracranial pressure syndrome and a frontal syndrom. Neurological examination revealed a right hemiparesis.

An MRI with and without injection of contrast, in axial, coronal and sagittal sequences in T1, T2, flair and Diffusion Weighted Intensity with and without gadolinium, revealed the presence of a left frontal tumor measuring 68 x 62 mm with two compartments : cystic and an enhanced mural nodule. Micro cystic necrotic lesions are visible in the solid portion. This lesion had a dural attachment in contrast enhanced images and it's surrounded by minimal peritumoral oedema with mass effect on adjacent structures. (Fig.1)

The diagnosis of cystic meningioma was mentioned ; however a cystic glioma was not eliminated.

Because of the intensity of headache, puncture of the cyst was performed bringing about 40 cc of xanthochromic cystic fluid.

In a second time, surgery through a frontal craniotomy was performed. Preoperatively, we observed a cystic component containing xanthochromic fluid and yellowish-gray coloration solid nodule which was non

hemorrhagic, and separated from the surrounding brain parenchyma by the cystic wall. The tumor was completely removed with its dural attachment.

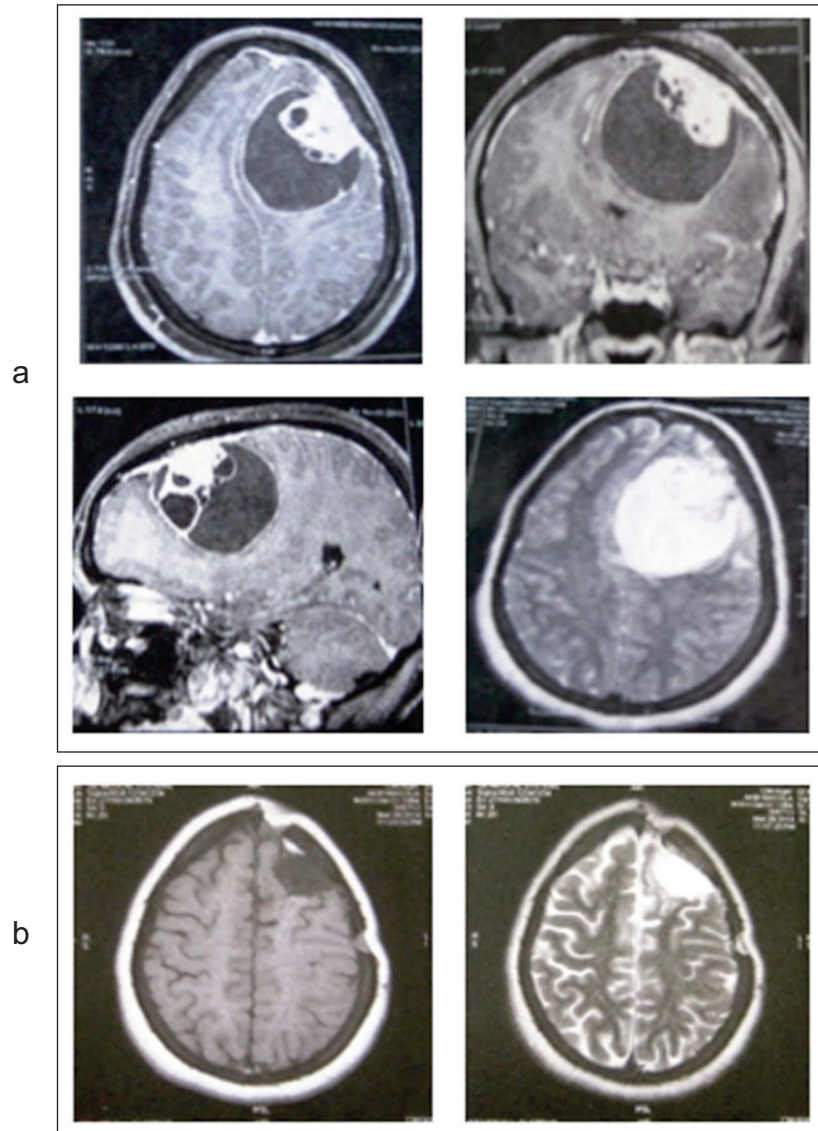
Histopathological examination revealed an atypical meningioma (Grade II meningioma).

The outcome was uneventful and the patient was discharged from high intra

cranial pressure (HIC) syndrome and from psychiatric disorders ten months later.

Seizures are stabilized under antiepileptic therapy (tegreol LP 400 mg)

A post operative brain MRI performed six months and one year later revealed a sequel ependymal cavity without any signs of recurrence.



**Figure 1 :**

- a/ Pre operative MRI with post contrast axial (T1), coronal (T1), sagittal (T1) and (T2) sequences revealing a cystic tumor in the left frontal area with minimal peritumoral oedema and dural attachment evident on T1 with contrast. Post operative MRI with (T2) and post contrast (T1) sequences shows no residual tumor or cyst

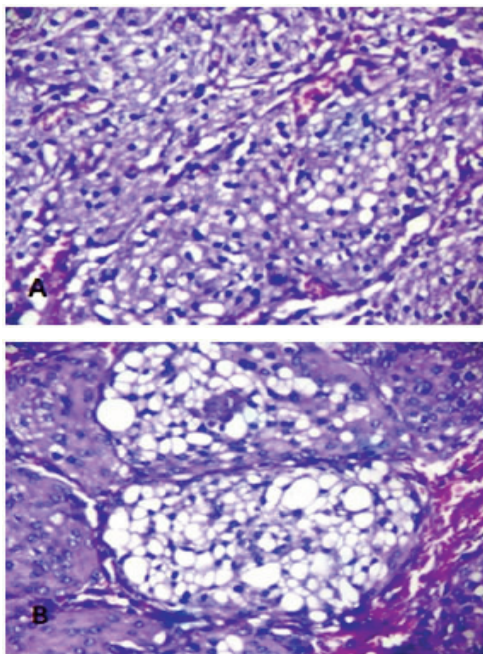
#### **HISTOLOGICAL - EXAMINATION**

The tumour shows the typical histological features with few nests of meningothelial whorls and the tumour cells having xanthomatous cytoplasm.

Brain invasion was observed. Mitosis and necrosis were absent

**IMMUNOHISTOCHEMISTRY :** The tumor cells shows immunore activity for Vimentin, Epithelial Membran Antigen (EMA) and S100 protein. Ki 67= 5%

**DIAGNOSIS IS A MICROCYSTIC  
MENINGIOMA WHO GRADE II**



**H & E : Histological features of microcystic meningioma**

- A: Cobweb architecture with xanthoma and xanthoma-like cells.  
B: Microcystic meningioma characterized by intercellular microcystic spaces.

**CASE 2**

Thirty one years old man without previous disease was admitted in our department for partial seizures which motivated the patient to consult 06 months later a neurologist who prescribed anti convulsivant therapy (depakine 500 mg).

Because the epileptic seizures became more and more frequent, an MRI with contrast was performed revealing brain tumor.

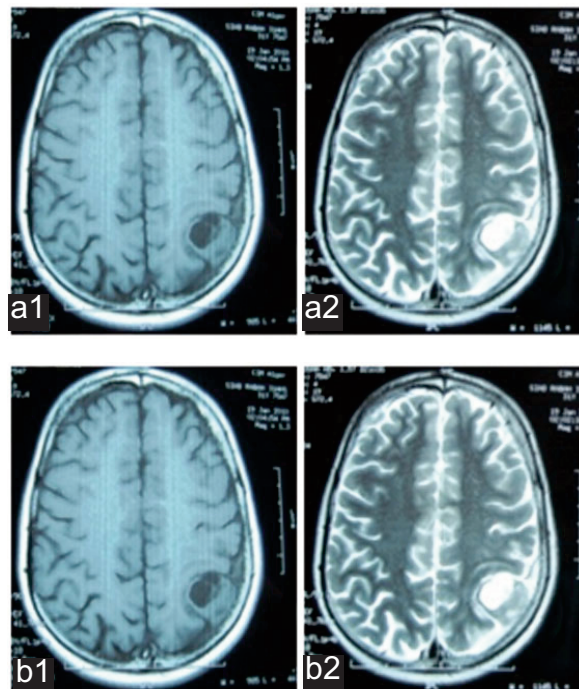
Neurological examination revealed high intracranial pressure (HIC) syndrom with right hemianesthesia.

An MRI with and without gadolinium showed a left parieto occipital tumor measuring 32x24 mm with two components cystic and solid, with minimal cerebral oedema. Contrast imaging revealed an enhancing tumor with dural attachment.

A preoperative diagnosis of cystic meningioma was made, but a glial tumor was also considered in the differential diagnosis. The tumor was completely removed with its dural attachment via a parieto-occipital craniotomy.

The histopathological examination revealed a diagnosis of angioblastic meningioma with brain neighborhood

aggression signs. Radiotherapy completed surgery. The post operative course was uneventful and seizures stabilized with antiepileptic therapy (tegretol LP 400 mg 1/2 cp per day). There was no residual tumor in follow-up cerebral MRI performed four years later.



**Figure 2 :**

- a/ Pre operative MRI with axial T2 and T1 without and after gadolinium injection shows a tumor in the left parieto-occipital area with peritumoral cyst and minimal cerebral oedema. Contrast imaging revealed an enhancing tumor without dural attachment.  
b/ Post operative MRI with axial T2 and post contrast T1, axial and sagittal shows no residual tumor or cyst.

**HISTOLOGICAL EXAMINATION :**

The tissue fragments received were fixed in 10 % buffered formalin and were processed routinely.

Hematoxylin and Eosin (H & E) stained sections showed vascular tumor consisting of dilated vascular spaces with intervening areas showing spindle to oval cells with abundant cytoplasm and oval vesicular nuclei.

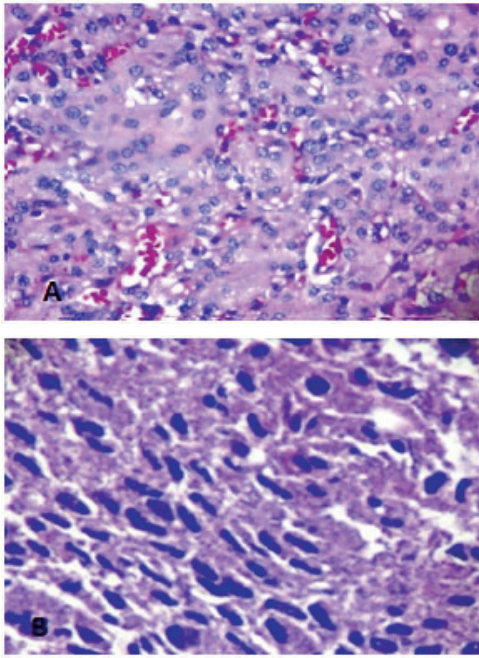
Brain invasion was noted

**IMMUNOHISTOCHEMISTRY :**

The tumor cells showed positivity for: Epithelial membran Antigen (EMA), Cytokeratin, Progesteron, Vimentin and negativity for GFAP and CD34



**DIAGNOSIS: ANGIOMATOUS MENINGIOMA  
WHO GRADE II**



**H & E / Histological features of angiomatous meningioma**

- a/ Angiomatous meningioma dominated by excessive vascularization with méningothélial tumour cells  
b/ Increased cellular, with high nuclear cytoplasmic ratio.

**CASE 3**

Twenty years old man without previous disease, presented 03 months ago with high intracranial pressure (HIC) syndrom, particularly visual disturbances (diplopia) and also behavior disorders (euphoria and exaltation mood).

Ophthalmic fundus revealed stage III papillary oedema.

A CT scan and MRI with and without contrast revealed a large left parietal mass measuring 64 x 60 x 70 mm in its main lines, heterogeneous with solid and cystic component.

The cystic component is spontaneously hypodense with ring enhancement after contrast injection. This lesion is surrounded by a large perilesionnel oedema, with signs of engagement.

T1, T2 and FLAIR sequences cerebral MRI with, with and without contrast showed an heterogeneous left parietal mass measuring 58 mm, with a cystic component appearing in hyper signalin T1,T2 and FLAIR with peripheral enhancement after contrast anda solid component measuring 40 x17 mm, hypo intenseon T1, iso-hyper

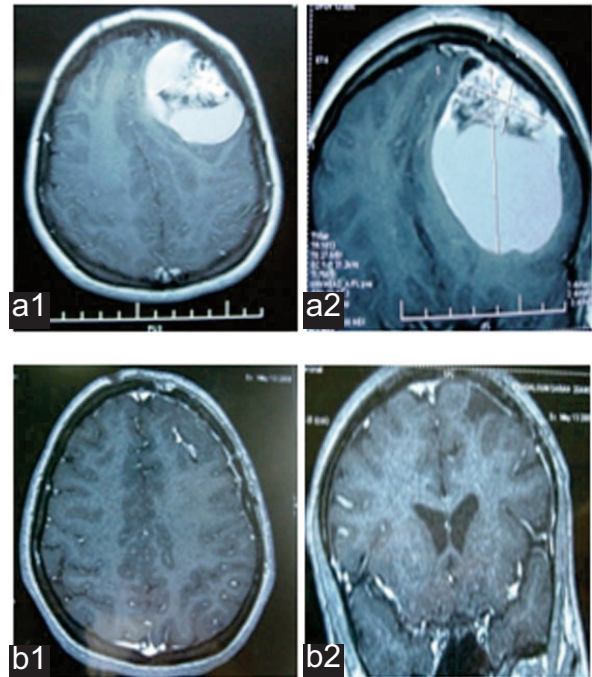
intense on T2, with heterogeneous enhancement after gadolinium.

Lesion was surrounded by a large perilesionnel oedema with dural attachment on T1 gadolinium sequences.

A total removal of cystic and solid mass was performed with coagulation of dural attachment.

The histopathological examination revealed a diagnosis of meningo theliomatous meningioma grade I.

The post operative course was favorable; the patient was discharged from its high intracranial pressure syndrom and controls MRI,10 years after showed no signs of recurrence.



**Figure 3 :**

- a/ Pre operative MRI with post contrast T1 axial and coronal sequences, revealing anheterogeneous left parietal masswith several cysts surrounding by a large cyst and a wide area of cerebral oedema. A coronal T1 sequence shows a dural attachment.  
b/ Post operative MRI with post contrast T1 axial and coronal sequences shows no residual tumor or cyst.

**HISTOPATHOLOGY :**

Tumour cells form lobules, some partly demarcated by thin collagenous septae.

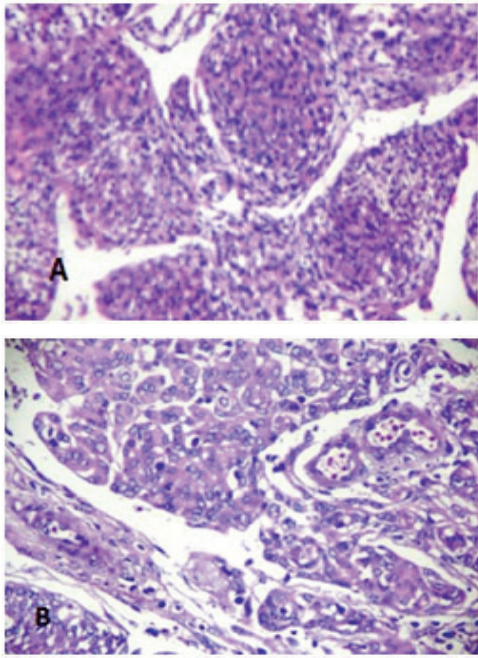
The tumour cells are largely uniform, with oval nuclea with delicate chromatin and intra nuclear inclusion.

Mitosis is absent

**IMMUNOHISTOCHEMISTRY:**

EMA (+), Vimentin (+), GPAF (-)



**DIAGNOSIS: MENINGOTHELIAL MENINGIOMA WHO GRADE I****H & E / Histological features of meningothelial meningioma**

- a/ Uniform, evenly spaced cells with indistinct borders create a syncytial pattern  
 b/ Typical intra nuclear inclusions.

**CASE 4**

A 45 years old woman with trisomy syndrome, presented 6 months ago with behavioral disorders such as aggression, isolation, semantic and mood disorders (laughing, crying) and suffered from sphincters disturbances, two months later.

Neurological examination revealed a right hemiparesis.

CT scan performed with and without injection of contrast showed a large left frontal mass measuring 73 x 64 x 70 mm, limited by a thin capsule with two components solid and cystic.

This lesion displaced the ipsilateral lateral ventricle and adjacent structures.

T1, T2 and FLAIR sequences brain MRI, with and without contrast depicted a left fronto parietal solid mass with many microcysts, measuring 64 x 71 x 72 mm and surrounding a cystic component.

Contrast imaging revealed an enhancing tumor with dural attachment.

This lesion displaced the frontal horn of the ipsilateral lateral ventricle and adjacent structures.

The patient underwent surgery with total resection.

The post operative course was good and patient was discharged from motor, sphincter and psycho intellectual disturbances.

Histological examination revealed an atypical meningioma.

On 15/09/14, the patient was admitted to medicine department for management of venous thrombosis of a right lower limb.

Physical examination on admission revealed an edema of the entire lower limb with local heat, Homan's sign positive. The origin of the thrombosis was associated with a postoperative alliment. However, an assessment of thrombophilia has been requested and was negative.

Liver function tests were disturbed counter indicating the initiation of oral anticoagulant treatment with Sintrom.

Doppler of the lower limbs revealed a deep right venous thrombosis.

CT scan and cerebral MRI showed left fronto-parietal hematoma with intraventricular hemorrhage.

After no treatment, an anticoagulant therapy (inolop0, 4cc subcutaneously/day) was instituted with biological control and elastic compression of both lower limbs.

The course of thrombophlebitis was favorable and control cerebral MRI showed sequelae cavity without hemorrhage.

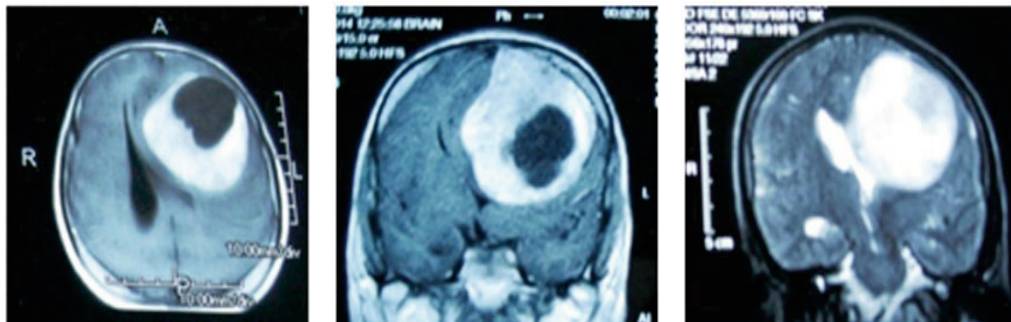

Figure. 4 : A/ Post contrast axial T1, coronal T1, sagittal T1 and coronal T2 sequences demonstrating a cyst with an enhancing mural nodule. No dural tail sign is evident to suggest an extra axial neoplasm.

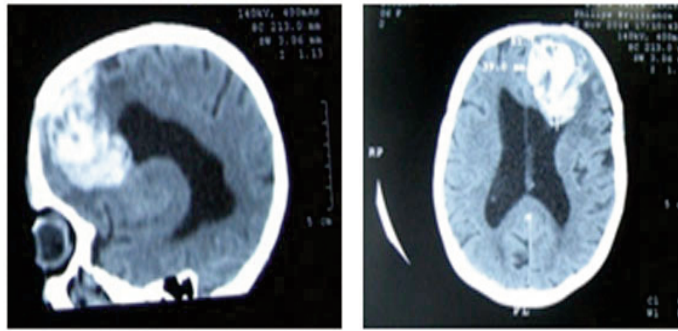


Figure. 4 : B/ Post operative scan with axial and sagittal sequences showing hematoma of postoperative cavity.

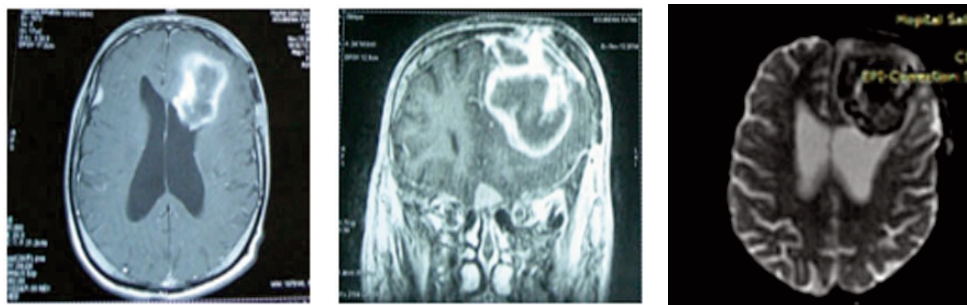


Figure. 4 : C/ Postoperative MRI with axial and coronal sequences on T1 with gado and axial sequences on T2 spin echo showing resorption of hematoma.

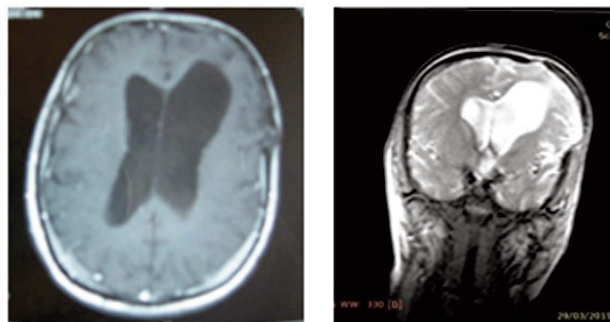
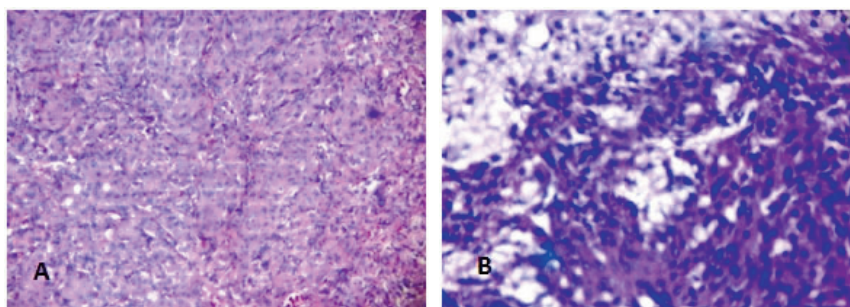


Figure. 4 : D/ Post operative MRI six months later, showing post operative cavity without residual tumoral and attraction of the horn of lateral ventricle.

**HISTOLOGIC AND IMMUNOHISTOCHEMICAL STUDY :** showed increased mitosis, high small cells components with high nuclear cytoplasmic ratio.

Immuno positivity for Vimentin, EMA, Cyto keratins. Ki 67 = 6%

**DIAGNOSIS : ATYPICAL MENINGIOMA WHO GRADE II**



**H&E : Histological features of Atypical meningioma**

- a/ Increased cellularity and uninterrupted patterness.
- b/ Smallcells with high nuclear cytoplasmic ratio and mitosis activity.



## DISCUSSION

Meningiomas are common benign tumors of the central nervous system accounting for 13 to 18% of intracranial tumours and are the most common extra cranial neoplasm [15, 11]

They are most often discovered in middle to late adult life. Authors reported that 90% of meningiomas are benign, 6% are atypical and 2% are malignant. [13]

Meningiomas are mostly known to be solid tumors. Cystic forms are uncommon, accounting for 4 to 7% of meningiomas [11, 4, 14]. Some authors [1,15] report an incidence varying between 2 and 4%.

Cystic meningioma is more common in pediatric patients than in adults [14]. The first description was reported by Penfield in 1932 [1,9]. Cushing and Eisenhardt reported 13 patients with cystic meningiomas in their series of 313 intracranial meningiomas.

Horsley and Olivercrona reported 177 cystic formations in their series of 1313 cases of meningiomas. [1].

Jung et al. reported 21 (5.5%) patients with cystic meningioma of 365 intracranial meningiomas [8].

The term of microcystic meningioma was suggested by Kleinman et al in 1980. In 1990, Ito et al proposed the term of "arachnoid trabecular cell meningioma" in order to avoid confusion with other type of cystic tumours. But, according to the new WHO classification of brain tumors, the term of cystic meningioma is more available [9].

Cystic meningiomas as classical forms occur between the fourth and the five decade. In our series, the age of patient ranged between 20 and 45 years. The female sex is slightly predominant such as other type of meningiomas. This preponderance was found in our study.

The most frequent location of cystic meningioma is the cerebral convexity followed by the parasagittal region. According to Zhang, the occurrence of cystic tumor on typical location of meningioma may facilitate the diagnosis [18].

In our series the frontal location was more common.

The clinical behavior of these tumors is similar to other form of benign meningiomas, according to location and size of tumors. Increased intracranial pressure, seizure, visual disturbances and motor weakness are the most common symptoms in the literature and in our study.

Some authors reported the rapid onset of symptoms which may be due to enlargement of cyst than to oedema or size of tumors [9]. This is in agreement with our study because, the onset of symptoms was rapid, ranging between three and six months in three patients whose cyst is large.

The use of CT and MRI has greatly facilitated the diagnosis of meningiomas with a histological predictive accuracy approaching 90% [15]. However, the presence of cystic component rare in meningioma may make it difficult to distinguish this tumour from other intra-axial cystic tumors such as glioma, hemangioblastoma or metastatic tumors with cyst.

Several authors believe that establish diagnosis of cystic meningioma based only on imaging is a challenge. Ferrante et al reviewed 166 of cystic meningiomas reported in the literature and noted that a correct preoperative diagnosis was made in only 12, 6% by angiography and 37, 9% by CT scan [6]

The presence of peritumoral oedema can be a misleading finding. In our three cases, oedema was large in only one case and suggested a diagnosis of cystic glioma. However, contrast enhancement of the dura attachment is of great value.

Coronal MRI with Gado will help to visualize the enhancing nodule component and its attachment to the dura (dural tail sign). Some authors noted that the existence of dural attachment in cystic meningiomas is not very common [5]. However, we detected dural attachment in two cases of our series.

The presence of meningeal vascularization on the angiographic study with external carotid injection can be an additional diagnostic key. In our series, none of the patients underwent a cerebral angiography.

The association of hemorrhage with meningioma is very rare. Cushing and Eisenhardt found no hemorrhage in their series of 313 meningiomas. Hoessly and Olivercrona in their series of 280 cases of meningiomas, there was no case of hemorrhage mentioned. However, Russel and Coll reported three cases of hemorrhagic meningiomas in their series of 131 cases. In our modest series, no case of hemorrhage was noted.

The pathogenesis of cystic meningioma is still not entirely known. So, several theories have been proposed. These include degeneration of tumour, secretion of fluid from tumor cells and loculated cerebro-

spinal fluid from scar tissue within or adjacent to the tumour [10].

According to Fortuna et al, intra tumoral cyst is the outcome of cystic degeneration, necrosis or haemorrhage within the tumor. However, peripheral cyst may represent a peripheral degeneration of an arachnoid cyst.[14]

Nauta et al classified cystic meningioma in four types according to the location of the cavity:

Type I: intra tumoral cyst is centrally located within the tumor.

Type II: intra tumoral cyst is peripherally located within the tumor.

Type III: peripheral cyst is located in the adjacent brain.

Type IV: peripheral cyst is located between the tumour and the brain.

According to Nauta and al classification, we detected type II in our first, second and third cases and type I in our fourth case.

The surgical removal of the cyst wall of cystic meningioma is controversial, but total surgical removal is recommended [15].

Cystic meningioma should be removed totally with the cyst wall in order to prevent recurrences. So, we performed total resection of cyst component as well as solid one in all patients. The cyst wall is sometimes difficult to remove from adjacent parenchyma. So, the incomplete resection can be followed by radiotherapy if histological examination revealed anaplastic or malignant meningioma. Radiotherapy followed surgery in one case of angioblastic meningioma with aggression signs of adjacent brain.

8% of meningioma are considered atypical (WHO grade II) and tend to have a higher incidence of recurrences. The presence of necrosis, excessive mitotic activity and signs of brain invasion are histological features of atypical meningioma. Histologically, it is characterized by increased cellularity and uninterrupted patternness. The cells are small with high nuclear cytoplasmic ratio and mitosis activity.

Immuno positivity for Vimentin, EMA, Cyto keratins and the Ki 67 = 6%

Three cases of our series are atypical meningiomas (one case is angiomatous meningioma characterized by a lower cellularity with numerous vessels and intra tumoral cystic changes and two cases microcystic meningioma characterized by intercellular microcystic spaces.

Meningothelial meningioma contains polygonal cells arranged in lobules, some

partly demarcated by thin collagenous septae. The tumour cells are largely uniform, with oval nuclei with delicate chromatin and intra nuclear inclusion. Mitosis is absent.

Immunohistochemistry showed positivity for EMA (+), Vimentin (+), and negativity for GFAP (-). In our series, meningothelial meningioma is found in one case.

Prognosis of cystic meningiomas depends on a variety of factors including, age of patients and associated comorbidities, location of the tumor, removal quality and histological type.

Immediate post operative course was uneventful for all patients.

Long term evolution varied between 03 months and 5 years was favorable. This was related to age of patients which were young, location of meningiomas (convexity), absence of comorbidities and histological type (meningotheliomatous meningioma in three cases and angioblastic meningioma with aggression signs of parenchyma in only one case. This last one was treated by surgery followed by radiotherapy.

## CONCLUSION

The preoperative diagnosis is essential in cystic meningiomas because it will certainly affect the surgical strategy and outcome of these patients. Dural attachment is detected on radiological evaluation; these may improve accuracy in diagnosis of cystic meningiomas.

The contrast enhancement of the cyst wall is a predictive factor of a malignant meningioma.

In these patients, the cyst wall should be totally removed in order to prevent tumour recurrences.

## BIBLIOGRAPHY

- 1] ABDEL-RAZEK.M, AL-AWADI.Y, AL-HASSAN. A. Cystic meningioma. Panarab journal of neurosurgery Vol. 13, NO. 1, 2009
- 2] BOGUSLAW M., DARIUSZ L., PAWEL K., KRZYSZTOF C. Cystic Meningioma Three Cases' Report. Department of Neurosurgery, State Medical Centre Opole, Poland
- 3] CHEN TY, LAI PH, HO JT, WANG JS, CHEN WL, PAN HB, WU MT, CHEN C, LIANG HL, YANG CF. Magnetic resonance imaging and diffusion-weighted images of cystic meningioma : correlating with histopathology. Clin Imaging 2004; 28 : 10-19.



- 4] CHONG K YI, RICARDO M BURGOS, TIMOTHY J BIEGA. Cyst with a mural nodule: unusual imaging characteristics of a cystic meningioma. *BMJ Case Reports*, 2014
- 5] EMEL AVC11, ADIL ÖZTÜRK2, İLYAS ÖZARDALI3, MURAT BEREKET1, HAMZA KARABAĞ1, SEYHO YÜCETAŞ1, AHMET ÇAKIR1. Cystic Meningiomas With Dural invasion in adults. *Journal of neurological sciences (Turkish)* 2005, Vol. 22, N° 3, pages 332-33
- 6] FERRANTE L, ACQUI M, LUNARDI P, QASHO R, FORTUNA A. MRI in the Diagnosis of Cystic Meningiomas : Surgical Implications, *Acta Neurochir* 1997; 139: 8-11.
- 7] GIUSEPPE PARISI, M.D., ROSARIOTROPEA, M.D., SALVATORE GIUFFRIDA, M.D., MARIA Lombardo, M.D, France sco Giuffrè, M.D. Cystic meningiomas, Report of seven cases. *Journal of Neurosurgery*, January 1986/Vol. 64/No. 1/P35-38
- 8] JUNG TY, JUNG S, SHIN SR, MOON KS, KIM IY, PARK SJ, KANG SS, KIM SH. Clinical and histopathological analysis of cystic meningiomas. *J. ClinNeurosci*.2005; 12: 651-5.
- 9] JUN HYUNG CHO, M.D.,1 KOOK HEE YANG, M.D., PH.D.,2HO YEAL ZHANG, M.D., PH.D.,2 JEONG-HAEKIE, M.D.3. Microcystic meningioma-unusual variant of meningioma *J Korean Neurosurg SOC* 34: 382-385, 2003
- 10] MITTAL.A, MD, KENNITH F. LAYTON, MD, S. SAM FINN, MD, GEORGE J. SNIPES, MD, MICHAEL J. OPATOWSKY, MD. Cystic meningioma : unusual imaging appearance of a common intracranial tumor. *Proc (Bayl Univ Med Cent)*. Oct 2010;23-4:429-431.
- 11] MITTAL.A, MD, KENNITH F. LAYTON, MD, S. SAM FINN, MD, GEORGE J. SNIPES, MD, AND MICHAEL J. OPATOWSKY, MD, JUN HYUNG CHO, M.D.,1 KOOK HEE YANG, M.D., PH.D.,2HO YEAL Microcystic meningioma- unusual variant of meningioma, *J Korean Neurosurg SOC* 34: 382-385, 2003
- 12] QASHO.R M.D., EPIMENIO R.O. Cystic meningioma: Neuro radiological (MRI, CT) and macroscopic intra operative appearance. *A case report Neuro surgical Review* 1998, Volume 21, Issue 2-3, pp 155-157
- 13] ROCKHIL JM. D ; PH. D, MRUGALA. M, M.D., PH.D., M.PH., AND CHAMBERLAIN.M, M.D. Intracranial meningioma: an overview of diagnosis and treatment. *Neurosurgical Focus* October 2007 / Vol. 23 / No. 4 Page E1
- 14] SAXENA.D, P ROUT, K PAVAN, B PHILIP. MRI Findings Of An Atypical Cystic Meningioma – A Rare Case. *Journal of Radiology*. 2012 Volume 14 Number 1.
- 15] TATLI.M, GUZEL.A, GOKSEL.H.M. Cystic meningioma report of three cases *Turkish Neurosurgery* 2006, Vol: 16, No: 4, 185-188
- 16] WAN X1, JIANG B, MA Z, WANG J, HOU Y, LIU Y. Diagnosis and treatment of cystic meningioma *Neurosurg Rev*. 2003 Jan;26(1):62-6. Epub 2002 Jun 11.
- 17] WEBER J1, GASSEL AM, HOCH A, KILISEK L, SPRING A. Intra operative management of cystic meningiomas. *Neurosurg Rev*. 2003 Jan ; 26-1: 62-6. E pub 2002 Jun 11.
- 18] ZHANG D, HU LB, ZHEN JW, ZOU LG, FENG XY, WANG WX ET AL. MRI findings of intracranial cystic meningiomas. *Clin Radiol* 2009 ; 64 792-800