

THE BONY SUBSTITUTION USING ORTHOTOPIC AUTOCLAVED ALLOGRAFT IN DOGS FEMUR

Reçu le 08/06/2008 – Accepté le 10/07/2009

Résumé

L'implantation de différentes longueurs d'un segment de greffe orthotopique allogénique autoclavé fixé par un enclouage centromédullaire et fil métallique dans le manche du fémur gauche chez onze chiens adultes dans le but de déterminer un pourcentage maximal de la substitution osseuse. Un suivi clinique d'évaluation de la boiterie ainsi qu'une série de radiographie ont été effectués après l'opération. En même temps, la comparaison d'implant entier avec un autre perforé. L'union osseuse a été constatée chez cinq chiens, suivie par une extraction du clou. La fracture de l'implant a été constatée chez trois sujets ainsi que la mort de deux autres pendant le suivi. Le pourcentage de la substitution a été évalué à 33% avec une longueur maximale de 6 cm. L'implant perforé a accéléré le processus de formation de cal.

Mots clés : substitution osseuse, allogreffe orthotopique autoclavé, fémur, chien

Abstract

Implantation of different lengths of orthotopic autoclaved allograft in the femur of dogs fixed with intramedullary pin and stainless steel wire has been performed in 11 dogs, to determine the maximum percentage of bone substitution, as well as, comparison of fenestrated and non fenestrated bony implants. Clinical lameness and serial post operative radiographs are evaluated. Bone union in five dogs, breaking of the implant in three cases and death of two dogs during the follow up has been observed. The maximum percentage of the bony substitution that could be applied successfully is about 33% with the maximum length of 6 cm. The rapid hard callus formation has been observed due to the use of perforated implant.

Key words: bony substitution, orthotopic autoclaved allograft, femur, dog.

K. AMARA¹
M. MELIZI²
M. BENAZZOUZ³
H. SHNAIN⁴

¹Institute of Veterinary Sciences, Tiaret University; Algeria.

²Department of Veterinary Sciences, Faculty of Sciences, Batna University; Algeria.

³Department of Veterinary Sciences, Faculty of Sciences, Constantine University; Algeria.

⁴Department of Surgery, College of Veterinary Medicine, Baghdad University; Iraq

ملخص

أجريت عملية غرس أطوال مختلفة لطعم عظم أنبوبي عريض اسوي معقمة بجهاز الموصل ومثبتة بالسفود الداخل النخاع و مثبتة بسلك معدني نصف حلقي في عمد عظم الفخذ الأيسر احد عشر كلبا بالغة لتحديد أقصى نسبة تعويض. كما أجريت مقارنة الغرسة غير المثقبة مع الغرسة المثقبة. و تم متابعتهم سريريا و شعاعيا.

النتائج كانت التحام كامل مع إزالة السفود الداخل العظم في 5 حالات, و ثلاثة حالات انكسار الغرسة, ونفق حالتين أثناء المتابعة و بئر طرف حالة وحدة. قدرت نسبة التعويض بـ 33% , كان أقصى طول 6 سم كما لوحظ عند استعمال الغرسة المثقبة تكون ثفن أسرع و أكثر صلابة.

استنادا لهذه النتائج , نتوصل إلى ان الطعم المتباين الاسوي المعقم بجهاز الموصل يتناسب هيكليا مع التعويض العظمي بمقدار حده 33% من الطول الكلي للعظم.

الكلمات المفتاحية : استبدال عظمي, الزرع المعقم, عظم الفخذ, الكلب.

The first successful autogenous bone graft in animals was recorded by Merrem, who obtained healing of bone plates removed by trepanation subperiosteally [1].

Since this first attempt the literature on the subject has grown prodigiously and contains a wide diversity of confusing opinions regarding the best type of graft and the fate of the graft after transplantation [2].transplantation of bone repairing skeletal injuries is a well- recognized surgical technique.

Graft material has consisted of cancellous bone [3], cortical bone [4], or corticocancellous bone [5]. Bone has been taken from the same individual (autograft) [6], from an individual of the same species (allograft) [7], and from an individual of a different species (xenograft) [8]. The material used has been fresh, stored, or processed. Bone grafts have loosely packed, or have been fixed within defects, using wires, pins, or plates [9].

Allogeneic cancellous bone grafts is frequently used during orthopaedic surgery in humans. Considerable morbidity is associated with autogenous cancellous bone grafting in humans, including prolonged surgical and anesthetic time, increased blood loss, risk of infection, structural damage at the donor site, and increased postoperative pain [10]. All these problems can be solved by using allogeneic autoclaved bone graft.

In veterinary medicine, allografts of cortical bone are readily obtainable and relatively inexpensive. They must be harvested and implanted under strictly sterile conditions [11]. For all these cited reasons, and the fact that there are so many different sizes of dogs, we report in the present paper a new method of bony substitution using autoclaved allograft.

MATERIAL AND METHODS

Experimental animals

Eleven locale breed dogs (three females and seven male), weighting 11 to 20 kg were used for the experiment.

A presurgical treatment was applied for each dog using antiparasitic drug and then kept in special cages to avoid motion.

Bone graft preparation

The bones were prepared from femur diaphysis of Euthanased dogs. They were harvested under complete aseptic operating room conditions, and skin preparation. Routine orthopaedic operative draping and gowning procedures using towels, double muslin drapes and surgical gloving was used during all bone harvests.

The bone was harvested minutes after the donor euthanasia. All muscles, bone marrow, and most of the periosteum were removed from the bone. Different lengths of bone grafts have been obtained from different donors to be used as substitute (Table 1). The harvested bone was double wrapped in muslin towels and autoclaved.

Operation procedure

Surgical operation was carried out under general anaesthesia using atropine sulphate (1mg/b.w) intramuscularly as preanaesthetic followed 10 minutes later by intramuscular administration of a mixture of xylazine (5mg/kg) with ketamine (15mg/kg).

Table 1 : Study design

Case	Date	Sex	Body Weight(kg)	Percentage Bony Substitution	Graft Length (cm)	Perforated Graft	Non Perforated Graft
1	31/11/97	male	15	42%	8		x
2	08/01/98	male	13	43%	7		x
3	20/01/98	male	12	33%	5		x
4	25/03/98	male	17	33%	6		x
5	29/04/98	female	12	41%	6		x
6	11/05/98	male	10	34%	6		x
7	09/06/98	male	14	42%	6		x
8	06/10/98	male	11	33%	5		x
9	26/10/98	female	20	32%	5	x	
10	31/10/98	female	14	23%	4	x	
11	19/11/98	male	13	11%	2		x

The curved skin incision is made just cranial to the femoral shaft. The biceps femoris muscle is encountered if the incision is directly located over the shaft; incision through this muscle is not the approach of choice.

After approaching the fracture by incising the fascia lata cranial to the biceps muscle, the vastus lateralis muscle is retracted caudally to allow visualisation of femur segment. Maximal stripping of the periosteum is done to check the integrity of the femur shaft.

The section length was measured by the prepared allograft. Appropriated length of the mid-diaphysis of femur was removed with an oscillating bone saw under constant irrigation with sterile saline. The bone grafts were then inserted into recipient, and minor adjustments were made to provide maximum contact conformity between the graft and host bone segments.

The fixation of the graft was ensured by intramedullary pin and metallic wire by suturing the proximal and distal interface.

The pin was placed in retrograde fashion, exiting proximally through the trochanteric fossa. The surgeon must extend the animal's hip joint and adduct the femur when passing the pin proximally to avoid the sciatic nerve as it passes over the great trochanteric notch. The pin was placed proximally before insertion of bone graft segment. Sufficient pin was used to fill the medullary canal at its narrowest point. The pin was then driven distally into graft segment first then distal host bone segment. The surgery site was irrigated with a sterile saline-neomycin solution. Soft tissue closure was routine. Procaine penicillin G (40.000 units/kg) was administered intramuscularly following surgery, and ampicillin (20 mg/kg) was given per os every eight hours for the next 10 days. Radiography was performed immediately after surgery to evaluate the alignment between the host and grafted segment, and thereafter as dictated by the clinical and radiographic progression of union.

RESULTS AND DISCUSSION

The results in these 11 cases are summarized in chart form (Table 2). Total graft incorporation was observed in the cases n° 4, 8, 9, 10 and 11.

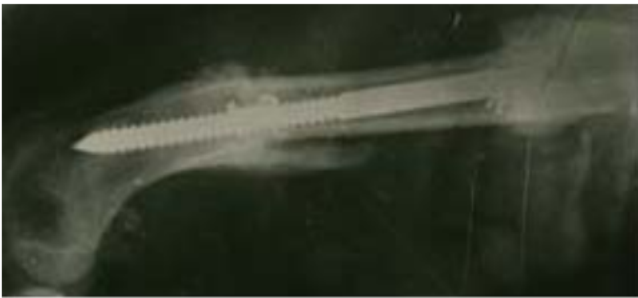Table 2: Clinical and radiographic data for 11 dogs which received different length of autoclaved allograft

case	Type of fixation	Complications	Radiographic Follow-Up	Clinical Follow-Up
1	pin	Severe bone instability	Limb amputation	Difficult weight bearing until amputation
2	Pin and wires	Hemorrhagic diarrhea	dead	Partial weight bearing during the first week
3	Pin and wires	none	Complete bridging	Full weight bearing occurred after two weeks
4	Pin and wires	none	Complete healing at proximal interface	Full weight bearing occurred after three weeks / Pin removed after 42 weeks
5	Pin and wires	Fracture of the graft after 20 weeks	Normal callus bridging/ graft fragility	pin protruding / partial weight bearing
6	Pin and wires	Complete Graft resorption after 18 weeks	Severe graft resorption/ important callus formation	pin protruding / partial weight bearing
7	Pin and wires	Fracture of the graft after 8 weeks	Normal callus bridging at distal interface/graft fragility	pin protruding / partial weight bearing
8	Pin and wires	none	Complete healing at the distal interface	Full weight bearing/ Pin removed after 16 weeks
9	Pin and wires	none	Complete fusion at the proximal and distal interface	Full weight bearing / Pin removed after 16 weeks
10	Pin and wires	none	Complete integration at the distal interface	Full weight bearing / Pin removed after 12 weeks
11	Pin and wires	none	Important callus formation	Full weight bearing / Pin removed after 12 weeks

Transient swelling of the limb at operative site was observed during the first post operative day in every dog. Each dog was bearing full weight on operated limb within two to four weeks following surgery except one (case n°1). In this case, the poor fixation using only pin without wire fixation produced limb rotation and permanent bone instability which prevented callus formation.

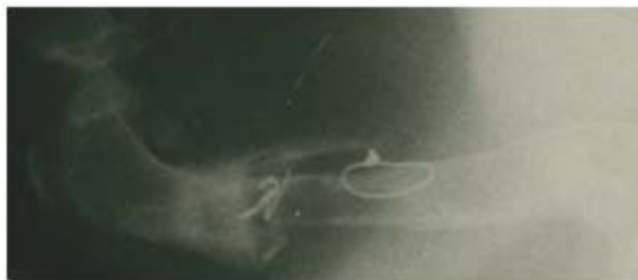The bone fracture and resorption were observed in the cases n° 5, 6 and 7. The complete callus bridging occurred after one month, which has been proved after the euthanasia of the case n° 3. During clinical follow up one dog had hemorrhagic diarrhea causing his death (case n° 2).

Bony substitution using segmental freeze dried and fresh cortical allograft has been performed with limited length for at least 5 cm [4, 12, and 13]. In retrospective analysis of failure in the repairing of severely comminuted long bone fractures using large diaphysal allograft the successful canine allograft was 6 cm [14]. Other studies of bony substitution with microvascular anastomosis mentioned the maximal length of 38% of the total femur length [15].



Case N° 3: (After 3 weeks) Disappearance of fracture line.

In our study, the maximal successful length of autoclaved allograft was 6 cm which represented 33% of the total femur length case n°4.



Case N° 4: (After 46 weeks) A complete graft healing in the proximal interface after pin remove can be observed.

The success rate for tubular allografts in the dog was 36% [16]. The success rate of the orthotopic autoclaved allograft was more important than the others (66.6%).

The most serious late complication of bony substitution was the fracture of the graft [17]. In our study the fracture

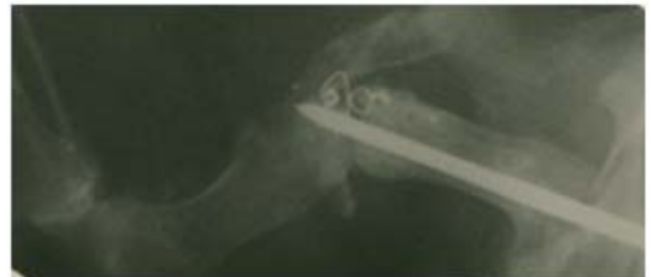
or high resorption of autoclaved graft was also the first problem cases n°5, 6, 7.



Case N° 5: (After 20 weeks) The fracture of the graft in his distal part.



Case N° 6: (After 3 weeks) Partial callus formation with graft resorption.



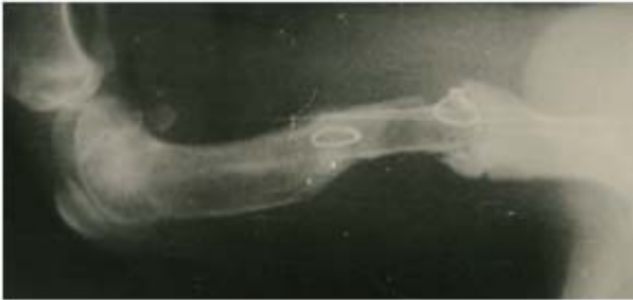Case N° 7: (After 8 weeks) Complete graft fracture.

The most common cause of delay or non-union is the inadequate fixation and the instability at the fracture site [18]. Either the pins were loose in the intramedullary canal, causing pain, or the proximal end of the pins protruding into the gluteal mass was causing pain on use, or the close proximity of the pins to sciatic nerve, or a combination of all three caused the dysfunction associated with the intramedullary pin [19]. Our results are in full agreement with this. The use of the intramedullary pin without wire fixation has showed high instability in the case n°1.

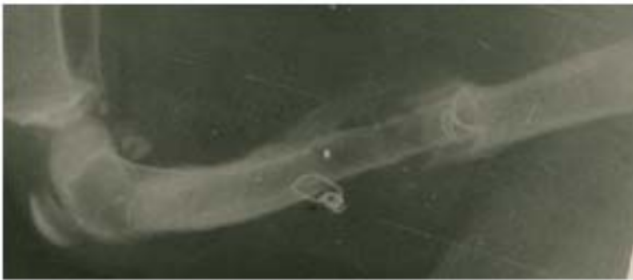
The formation of a progressive wall of periosteal as an attempt to bridge each interface started usually near the distal interface, this may have been due to the frequent problems of instability [12]. Similar problem occurred in case n° 4 figure 11 with delayed callus formation in the proximal interface

It must be kept in mind that in patients who are heavy or very active the survival of the implant may be hazardous [20]. The heaviest dog in our study was 20 kg (case n°9) and the graft was fenestrated, this case showed normal bone healing.

Cortical union usually occurred shortly after complete periosteal bridging. The approximate time of cortical union at the proximal interface for the fresh cortical autograft was 12 weeks and 15 weeks in both the freeze-dried and fresh cortical allograft. At the distal interface, these values were 11 weeks in fresh cortical autograft and 18 weeks in the freeze-dried and fresh cortical allograft [12]. In our study delayed union at the proximal interface has been observed in the cases n° 4 and 11 and at the distal interface in cases n° 8, 9 and 10.



Case N° 8: (After 20 weeks) Three weeks after pin removing, we can observe the complete disappearance of fracture line.



Case N° 9: (After 20 weeks) Complete integration at the distal interface after pin remove.



Case N° 10: (After 12 weeks) Complete union is observed in the distal interface.

The cortical union at the proximal interface occurred after 8 weeks in the case n° 11 and after 12 weeks at the distal interface in the cases n° 8 and 9. In the case n° 10 the cortical union at distal interface occurred after 13 weeks and after 18 weeks at the proximal interface in the case n° 4. The complete callus bridging with disappearance of fracture line was observed after 3 weeks in the case n° 3.

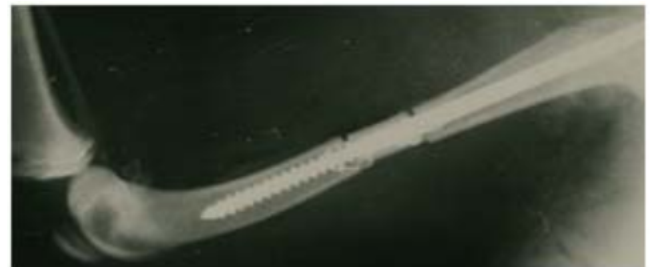Ordinarily, fixation devices are removed only after radiography confirms clinical union. In most cases with

diaphysal graft the bone plate was removed 18 months postoperatively [19]. In the present study a partial weight-bearing was observed from the third day. After 12 weeks the pins were removed and the most dogs recuperated gradually a complete weight-bearing.

The use of fenestrated allograft has showed rapid callus bridging and high stability this is due to the penetration of the callus in the holes, and the contact of the internal and external callus. The fenestration didn't affect the graft resistance; this can be proved by the fact that the heaviest dog had the fenestrated graft (case n° 9 and 10). The fenestration disappears rapidly after pin remove (case n° 10).



Case N° 10: (After 15 weeks) Complete bone union occurred in each interface after pin remove.



Case N° 11: (Postoperatively)



Case N° 11: (After 5 weeks) We can observe in this radiography the successful callus bridging in each interface.

CONCLUSION

According to these findings, the orthotopic autoclaved allograft is determined to be structurally adequate for reconstruction of long bone, with a limit of 33% of total length, and the fenestrated bony implant is more suitable for the callus formation and fixation of callus than the non

fenestrated. The use of intramedullary pin as graft fixation must be reinforced by metallic wire suturing.

REFERENCES

- [1]- Bowerman J.W. and Hughes J.L. "Radiology of bone graft" Clin North Am., Vol 13, (1975), pp 67-77.
- [2]- Peer L.A. "Transplantation of bone in animals" Transplantation of tissues, Vol II, Williams & Wilkins Company (1955), pp 152-179.
- [3]- Souter W.A. "Autogenous cancellous strip grafts in the treatment of delayed union of long bone fractures" J Bone Joint Surg (Br), (1969), Vol 51, pp 63-75.
- [4]- Albee F.H. "Fundamentals in bone transplantation " J Am Med Assoc, (1923), Vol 81, pp 1429-1432.
- [5]- Brinker W.O., Flo G.L., Braden T. "Removal of bone plates in small animals" J Am Anim Hosp Assoc, (1975), Vol 11, pp 577-586.
- [6]- Enneking W.F., Morris J.L. "Humain autologous cortical bone transplants" Clin Orthop, (1972), Vol 87, pp 28-35.
- [7]- Henriksen P. "Entire segment bone transplant in a cat" J Am Vet Med Assoc, (1979), Vol 174, pp 826-828.
- [8]- Hamon P. "Processed heterogenous bone implants as grafts in spinal surgery" Acta Orthop Scand, (1964), Vol 35, pp 98-116.
- [9]- Wilson J.W., Rhineland F.W.,and Stewart C.L. "Vascularization of chip bone graft" J Am Vet Res, Vol 46, N° 8, pp 1691-1699.
- [10]- Kerwin S.C., Lewis D.D., Elkins A.D., Olivier J.,Pechman R. "Deep-frozen allogeneic cancellous bone graft in 10 dogs" Vet Surg, (1996), Vol 25, pp 18-28.
- [11]- Friedlaender G.E. "Currents concepts review bone-banking" J Bone Joint Surg, (1983), Vol 64A, pp 307-311.
- [12]- Schena C.J., Mitten R.W.,and Haefle W.D. "Segmental freeze-dried and fresh cortical allograft in canine femur: A sequential radiographic comparison over a one-year time interval"J Am Anim Hosp Assoc, (1984), Vol 20, pp 911-925.
- [13]- Schena C.J., Mitten R.W.,and Haefle W.D. "Segmental freeze-dried and fresh cortical allograft in canine femur: A sequential radiographic comparison over a one-year time interval"J Am Anim Hosp Assoc, (1985), Vol 21, pp 193-206.
- [14]- Henry W.B.,and Wadsworth P.L. "Retrospective analysis of failures in the repair of severely comminuted long bone fractures using large diaphyseal allografts" J Am Anim Hosp Assoc, (1981), Vol 17, pp 535-546.
- [15]- Szentimrey D., Fowler D., Johnston G., Wilkinson A. "Transplantation of the canine distal ulna as a tree vascularized bone graft" Vet Surg, (1995), Vol 24, pp 215-225.
- [16]- Henry W.B.,and Wadsworth P.L. "Diaphyseal allograft in repair of long bone fractures" J Am Anim Hosp Assoc, (1981), Vol 17, pp 525-534.
- [17]- Parrish F.F. "Allograft replacement of all or part of the end a long bone following excision of a tumor: Report of twenty-one cases" J Bone Joint Surg, (1973), Vol 55A, pp 1-22.
- [18]- Boudrieau R.J. "Delayed union; non-union and malunion" In saunders Manuel of Small Animal Practice.Edited by S.J. Birchard & R.G. Sherding, WB Saunders Co, pp 1096-1100.
- [19]- Braden T.D.,and Brinker W.O. "Effect of certain internal fixation devices on functional" J Am Vet Med Assoc, (1973), Vol 162, N° 8, pp 642-647.
- [20]- Galante J.O., Rostoker W.,and Doyle J.M. "Failed femoral stems in total hip prostheses"" J Bone Joint Surg, (1975), Vol 55A, pp 230-236.

