

Administering ketoconazole (25mg/Kg) For 14 Days in male wistar rat provokes testicular damage accompanied by changes in testosterone levels and immune function

Kamilia Guedri, Hacène Frih, Aziez Chettoum, Asma Latreche, Leila Sahraoui, Nadia Boukhris & Abdelkrim Tahraoui.

Laboratoire de Neuroendocrinologie Appliquée, Département de biologie, Faculté des Sciences Université Badji Mokhtar Annaba. BP12, Annaba 23000, Algérie

Révisé le 19/03/2013

Accepté le 11/09/2013

ملخص

الهدف من هذه الدراسة هو الكشف عن تأثير المعالجة متوسطة المدى على ذكور الفئران البيضاء من سلالة وستار بواسطة جرعة عالية التركيز (25مغ/كغ) من الكيتوكونازول على الجهاز المناعي والتكاثري (الخصيتين). تم إعطاء هذه الجرعة للفئران البيضاء من سلالة وستار عن طريق الفم للمدة 14 يوم. أدى الكيتوكونازول إلى تغيير (زيادة الوزن النسبي للغدة السعترية والغدة الكظرية وكذا زيادة في وزن المخ مع انخفاض في وزن الخصيتين). ويرجع هذا إلى إتلاف للخلايا على مستوى نسيج الخصيتين مما أدى إلى انخفاض في نسبة التستسترون مع انخفاض مناعي (نقص في عدد اللمفاويات وزيادة في عدد الكريات الدموية البيضاء المتعادلة) هذه التغيرات في وزن الجسم ووزن بعض الأعضاء ترجع إلى عدة أسباب حيث لعبت فيها الجلبيكوكورتكودات دور المتحكم الرئيسي.

الكلمات المفتاحية: كيتوكونازول - التستسترون - الانخفاض المناعي - إتلاف الخصية .

Résumé

L'objectif de cette étude est d'explorer les effets du traitement subchronique des rats mâles Wistar par une forte dose de KTCZ sur les systèmes immunitaires et gonadotropes (testicules). Le KTCN (25mg/kg) a été administré par voie orale à des rats Wistar mâles pendant 14 jours.

Le ketoconazole a entraîné un changement dans le poids (augmentation du poids relatif du thymus, des glandes surrénales et du cerveau et une diminution du poids des testicules), des dommages au niveau des tissus testiculaires et enfin une diminution de la testostéronémie accompagnée d'une immunodépression (diminution des lymphocytes et augmentation des neutrophiles).

Ces modifications du poids corporel et des tissus pourraient avoir plusieurs origines avec les glucocorticoïdes comme chef d'orchestre.

Mots clés: Ketoconazole – Testostérone - Immunosuppression - Dommages testiculaires.

Abstract

The objective of this study is to explore the effects of subchronic treatment of male Wistar rats with a high dose of KTCZ on immune and gonadal changes (testes). KTCN (25mg/kg) was administered to male Wistar rats orally for 14 days.

Ketoconazole generated weight changes (increased relative weight of thymus, adrenals and brain and decreased weight of testes), testicular tissue damage and a decrease in testosterone serum accompanied by immunosuppression (decrease in lymphocytes and increase in neutrophilia levels).

These changes in body weight and tissue could have several origins which glucocorticoids play the role of conductor.

Keywords: Ketoconazole - Testosterone - Immunosuppression - Testicular damage.

* Corresponding Author: frihhacene@yahoo.fr

1. INTRODUCTION

In the past thirty years, a series of studies has demonstrated the existence of anatomical and functional links between the immune and endocrine systems. Since the publication of Ader [1], researchers have begun to focus on the links that exist between the psyche, central nervous system and immune system. Speculation on this subject gave rise to new disciplines, including psychoneuroimmunology. In this context, a series of research studies shows that mental disorders, specially depression, can cause changes in immune function and inflammatory responses and affects the vulnerability of the body [2-6].

Depressed patients have been subject to numerous studies in psycho-neuroimmunology. Initially, it was mainly to test the hypothesis of the relationship between depression and mental defenses. Indeed, some authors observed that depressed patients generally exhibit lymphopenia, reduced lymphocyte-proliferative response to mitogen and reduced non-specific cytotoxic activity of NK (Natural Killer) cells [7].

Recent data show that, despite the relative disparity of the results, depressed patients do not always exhibit a generalized immunosuppression (as suggested by the studies conducted on the effects of stress on immune responses), but sometimes it can show an activation of the immune system in acquired immunity [5]. On the basis of the observation on the effects of proinflammatory cytokines released by monocytes and macrophages on mood and behavior, the macrophage theory of depression (which assigns a role of that immune activation in the pathophysiology of depression) was proposed [8].

Moreover, it was observed that high levels of cortisol play a role in the abnormalities of depression [9, 10] and antidepressants can normalize levels of cortisol [11]. As such, inhibitors of the biosynthesis of cortisol, for example, ketoconazole (KTCN), were used as a strategy for the palliative treatment of depressive episodes [12, 13].

Ketoconazole (KTCN) is an antifungal drug with a broad spectrum activity and a member of imidazole family [14]. It reduce immobility in the forced swimming test (antidepressive-like effect) and anxiety at elevated plus-maze test [15]. The KTCN can induce dose-dependent decrease in serum testosterone levels in patients [16] and rats [17, 18]. It was reported that the KTCN inhibits C17-20 lyase, which blocks the

conversion of 17 α -hydroxyprogesterone to androstenedione [19]. In adult male, gynecomastia and azoospermia were reported at therapeutic doses of KTCN [20].

The aims of this study is (1) to explore the effects of subchronic treatment with high dose of KTCZ (25mg/kg) in male Wistar rats on immune and gonadal changes, and (2) to identify the mechanisms that may give rise to gonadal dysfunction. Investigations on some immune and gonadal functions were carried out through estimation of some biological parameters; such as relative organ weights (brain, thymus, adrenals and testes), testosterone and testicular histology.

2. MATERIAL AND METHODS

Experimental study was focused on adult male Wistar rats aged 6 months and weighted 250g \pm 10g. The experimental protocol was approved by the Scientific Committee of the faculty of science Badji Mokhtar University that is consistent with the principles of Animal Health (NIH Publication No. 85-23, revised 1985). The animals are reared in polyethylene cages. After an adjustment period of 4 weeks to environmental conditions of the experiment room (humidity, temperature), rats were divided into two experimental groups: control group (C; n = 8) that was used as placebo and was given 1 ml of saline by gavage. and treated group by cortico-blocker, ketoconazole (KTCZ; n = 8). Each rat was housed individually in the cage (35.6 cm x 15.2 cm) for a week and all animals were subjected to natural photoperiod (14-h light: 10-h dark cycle).

2.1 Administration of ketoconazole, dissection and removal of organs and blood

The KTCZ (25 mg / kg) diluted in NaCl (9 g/l) was administered orally daily in the morning at the same time for 14 days [15].

On the 15th day of treatment, rats were sacrificed by cervical dislocation. An incision was made from the urogenital opening to the manubrium. Testis, thymus, adrenal glands and brain were rapidly removed under ice using tweezers, weighed and fixed with formalin, and blood sample was collected. Cells counting was performed quickly on a multi-parameter automated analyser (ERMA PCE-210 Full automatic blood cell counter). Plasma samples were aliquoted and stored at -20 ° C.

2.2 Testicular histology

We used the conventional coloration method of hematoxylin-eosin (HE): The nuclei are stained blue by hematoxylin and the cytoplasm red by eosin. Photographs were taken in 640 x 480, with 0.4 megapixel digital camera built into the microscope American Optical.

2.3 Determination of plasma testosterone by ELISA

Testosterone was assayed by the conventional ELISA method. Measures were carried out using a TECAN ELISA reader equipped with Magellan computer software that automatically calculates the standard range and gives directly the value of testosterone to the desired unit.

2.4 Statistical analysis

All results are expressed as the mean \pm SEM (Standard Error of the Mean) and reported in tables. Statistical analysis was performed using MINITAB statistical software based on the comparison test of means (Student t) with samples treated/KTCN compared with control samples.

3. RESULTS

3.1 Change in hematological parameters in treated and control groups

Immunosuppression was observed in treated KTCN animals. This is evidenced by a non-significant decrease in the number of total leukocytes (Tab. 1) (KTCZ: 3.74 ± 1.44 . C: 4.88 ± 1.10) and lymphocytes (KTCZ: 45.71 ± 7.49 ; C: 66.21 ± 13.00). However, rats under KTCZ exhibited a significant increase in the rate of monocytes (KTCZ: 38.47 ± 6.68 ; C: 19.99 ± 5.88) and the neutrophilia count (KTCZ: 37.63 ± 9.57 ; C: 24.80 ± 5.99).

3.2 Change in testosterone level in treated and control groups

Testosterone dropped significantly in animals treated KTCN relative to control groups (KTCZ: 1.42 ± 0.48 C: 3.08 ± 1.96) (Tab. 2).

This shows the effectiveness of the KTCN treatment.

3.3 Change of relative organ weights

The estimation of relative organ weights (Tab. 3) shows that the testes relative weight fall significantly in treated compared to controls rats (C: 0.038 ± 0.003 KTCN: 0.019 ± 0.001), whereas the other organs (thymus, brain and adrenal) exhibited a gain in weight following administration of sub chronic KTCN [Thymus (C: 0.042 ± 0.005 . KTCN: 0.082 ± 0.004), brain (C: 0.015 ± 0.001 ; KTCN: 0.019 ± 0.002) ; adrenals (T: 0.010 ± 0.001 ; KTCN: 0.020 ± 0.001)].

Table 1. Change in the formula for blood counts: total leukocytes (cells $\times 10^3$), lymphocytes (%), monocytes (%) and neutrophils (%)) in Wistar male rats treated with ketoconazole and controls.

Groups/parameters	C	KTCZ
Total leukocytes (cellules $\times 10^3/\mu\text{l}$)	4.88 ± 1.10	3.74 ± 1.44
Lymphocytes (%)	66.21 ± 13.00	45.71 ± 7.49 ***
Monocytes (%)	19.99 ± 5.88	38.47 ± 6.68 ***
Neutrophils (%)	24.80 ± 5.99	37.63 ± 9.57 **

(n=8 ; * p < 0.05 ; ** p < 0.01 ; *** p < 0.001)

Table 2. Change in testosterone (ng/ ml) in Wistar male rats treated with ketoconazole and control

Groups/parameters	C	KTCZ
Testosteronemia (ng/ml)	3.08 ± 1.96	1.42 ± 0.48 ***

(n=8 ; * p < 0.05 ; ** p < 0.01 ; *** p < 0.001)

3.4 Histopathology of the testes of male wistar rats controls and treated with ketoconazole

Testis of rats controls (Fig. 1A.) show normal histological appearance of seminiferous tubules in control group with evidence of spermatogenesis, well organized distribution of cells in the seminiferous epithelium.

Testis of rats administered with KTCZ for 2 weeks (Fig. 1B.) show clearly many histopathological changes. In Figure 1.B,

KTCZ induce severe testicular degeneration, germinal cells necrosis, tubular atrophy, necrosis and disintegration of spermatocytes

from basement membrane and disorganisation in germinal.

Table 3. Change in relative organ weights (g/100g) of testes, brain, thymus and adrenal glands in treated and control groups.

Groups / relative weights (g/100g)	Testes	brain	Thymus	adrenal
C	0.038 ± 0.003	0.015 ± 0.001	0.042 ± 0.005	0.010 ± 0.001
KTCN	0.019 ± 0.001 ***	0.019 ± 0.002 *	0.082 ± 0.004 ***	0.020 ± 0.001 **

(n=8 ; * p < 0.05 ; ** p < 0.01 ; *** p < 0.001)

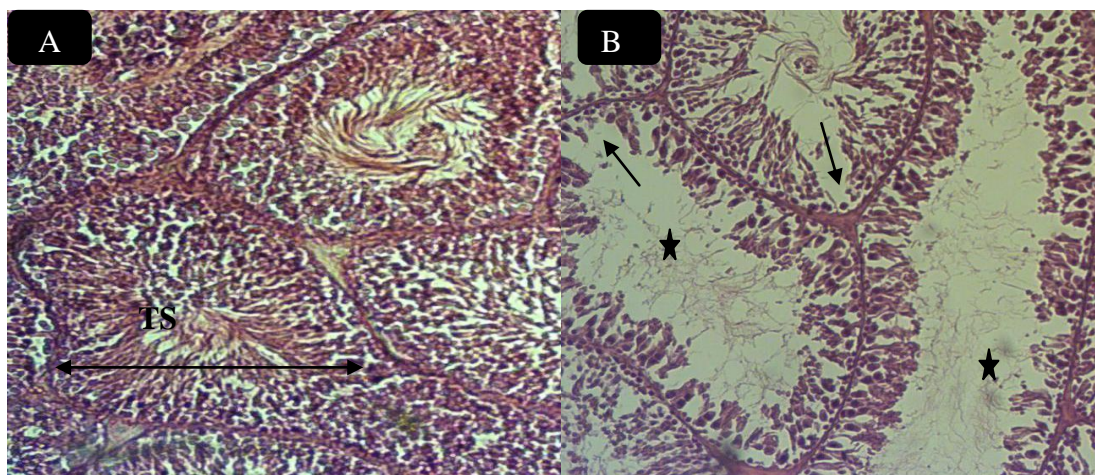


Figure 1. Microphotograph of the seminiferous tubules Testis under the optical microscope photographs (H & E, X100).

A. Testis of control rats show normal histological appearance of seminiferous tubules (TS) with evidence of spermatogenesis, well organized distribution of cells in the seminiferous epithelium.

B. Testis of rats administered with KTCZ for 2 week show clearly many histopathological changes. KTCZ induce severe testicular degeneration, germinal cells necrosis (*) in seminiferous tubules, tubular atrophy, necrosis and disintegration of spermatocytes from basement membrane and dis

Nb: The width of the field with each objective is: 4x = 3400, 1333 = 10x, 40x and 100x = 340 = 133 microns.

4. DISCUSSION

In this study, the treatment of animals by KTCN caused a significant increase in the thymus weight, adrenal and brain and a decrease in testicular weight compared to control animals (Tab. 3). Figure 1B shows clearly an alteration of testicular tissue. These changes in body weight and tissue could have several origins where the glucocorticoids play the role of conductor. These hormones have ubiquitous effects and have receptors at most

body cells (except erythrocytes). Glucocorticoids are known to have anti-inflammatory and immunosuppressive effects. The immunosuppressive action of glucocorticoids is mediated by a direct cytolytic effect through inhibition of lymphocyte function, or indirectly through soluble suppressor mediators [21]. The administration of glucocorticoids in vivo results in a pronounced thymic involution in mice [22]; the adrenalectomy in mice leads to a significant increase in weight of thymus and

spleen and increased numbers of splenic T lymphocytes. In our experimentation, thymic weight variation was observed following subchronic administration of high KTCN dose (25mg/kg) (Fig. 1).

In return, the thymus may also influence adrenal function. Indeed, it was observed that transplantation of new born's thymus in nude mice increased their adrenal weights [23]. Kruger *et al.* (1989) [24] suggested that this increase in adrenal weight is probably mediated by the secretion of TSH by lymphocyte cell.

It has been demonstrated that IL-2 and IL-6 induce the proliferation of pituitary cells in vitro [25]. Cytokines may have a direct effect on pituitary since PRL and GH-secreting cells express IL-2 receptors [25], or an indirect effect by inducing the secretion of CRH (Corticotropin Releasing Hormone) [25] which plays an important trophic role on the adrenal glands.

Our results show that decrease in testicular weight (Tab. 3) and plasma testosterone level (Tab. 2) in treated animals may reflect either the direct inhibition by KTCN or an effect mediated by the HPA axis. A study by Lambert *et al.* (1986) [27] showed that KTCN is rather more effective (as an inhibitor of steroidogenesis in vitro) in testicular cells more than in adrenal cells, but the inhibition is completely reversible in both cell types [27]. Sex steroids are known to depress immune function [28]. The physiologic thymic involution that starts at puberty may be attributed to high levels of sex steroids. However, the thymic involution is a reversible phenomenon. In mice and rats, atrophy of the thymus at any age can be reversed, and the thymus can regrow after gonadectomy (testicular or ovarian) [29-31].

The restoration of thymic size after gonadectomy is provisional and is observed for several weeks. This restoration thymus can be explained by a decrease in the suppressive effect of sex steroids [30]. Moreover, thymic hyperplasia is rather dependent on the alteration of the negative feedback of sex steroids on the hypothalamic-pituitary hormones and hypothalamic play a strong trophic role on the thymus. This concept was supported by the fact that thymic hyperplasia after gonadectomy does not happen in hypophysectomized rats [32].

In their study on Wistar male rats, Smagin and Goeders (2004) [33], demonstrated that chronic treatment with high KTCN dose (25mg/kg) causes a significant increase in thymus weight and adrenal. CRH content in several brain

structures (amygdala, median eminence, paraventricular and raphe nuclei) and plasma ACTH increase significantly. These results were also obtained in humans where it was found that chronic administration of KTCN generated a very significant elevation of plasma ACTH [34]. The inhibition of plasma corticosterone by KTCN may have resulted in the rapid activation of feedback mechanisms at pituitary and caused the discharge of ACTH. This increased secretion of ACTH tends to compensate lower glucocorticoids concentrations which take place under the effect of KTCN to maintain homeostasis by acting on the adrenal glands and causing, therefore, the adrenal hyperplasia. In addition, the administration of KTCN decreases cortisol and testosterone secretion respectively from ACTH-stimulated adrenal cells and LH-stimulated Leydig cells [27].

The gonadotropin axis is inhibited at all levels by various components of the HPA axis [35-37]. In the hypothalamus, the CRH inhibits GnRH in the arcuate nucleus. This effect could also be mediated by β -endorphin [38]. In addition, glucocorticoids exert inhibitory effects on the hypothalamic GnRH neurons and gonads, causing a decreased sensitivity of target tissues to sex steroids (peripheral resistance) [36]. It is interesting to note that during the inflammation, circulating cytokines suppress reproductive function by activating the hypothalamic secretion of CRH and POMC-like peptides and thus inhibit ovarian and testicular steroidogenesis [39, 40].

5. CONCLUSION

The present study was carried out in order to evaluate the effects of an antifungal drug ketoconazole, an imidazole derivative, inhibitor of gonadal and adrenal steroidogenesis, on the immune system and gonadal function in male Wistar rats. This issue is summarized in the fact that administration of high dose ketoconazole (25 mg/ kg) for 14 days resulted in testicular damage revealed by reduced testis weight and testosterone serum decrease. Immunosuppression is evidenced by a decrease in the number of lymphocytes and an increase in the number of neutrophilia. Weight changes are the increase in weight of thymus, brain and adrenal and the decrease testicular weight. In this study, anatomical and functional links between the immune and endocrine system (gonadal) we observed. The interactions between these major systems of intercellular

communication are evidenced mainly through the involvement of adrenal and gonadal steroids on one hand, and the soluble mediators of the immune system (cytokines, growth factors) on the other hand. Finally, it is worth studying the effectiveness of immunosuppressant agent (Cyclosporine) and anti-oxidants on the damage caused by ketoconazole, follow the expression through the study of animal behavior and explore the parameters of oxidative stress.

REFERENCES

- [1] Ader R. 1981. Psychoneuroimmunology. *Academic Press, New York*. 321.
- [2] Tecoma E.S. & Huey L.Y., 1985. A psychic distress and immune response. *Life Science*, 36 (19): 1799-1812.
- [3] Herbert T.B. & Cohen S., 1993. Depression and immunity: A meta-analytic review. *Psychological Bulletin*, 113: 472-486.
- [4] Makino M., Kitano Y., Hirohashi M. & Takasuna K., 1998. Enhancement of immobility in mouse forced swimming test by treatment with human interferon. *European Journal of Pharmacology*, 356 (1): 1-7.
- [5] Maes M., Lin A.H., Delmeire L., Van Gastel A., Kenis G., De Jongh R. & Bosmans E., 1999. Elevated serum interleukin-6 (IL-6) and IL-6 receptor concentrations in posttraumatic stress disorder following accidental man-made traumatic events. *Biological Psychiatry*, 45 (7): 833-839.
- [6] Deak T., Bellamy C. & D'Agostino L.G., 2003. Exposure to forced swim stress does not alter central production of IL-1. *Brain Research*, 972(1-2): 53-63.
- [7] Zorilla E.P., Luborsky L., McKay J.R., Rosenthal R., Houldin A. & Schmidt K., 2001. The relationship of depression and stressors to immunological assays: a meta-analytic review. *Brain, Behavior and Immunity*, 15 (3): 199-226.
- [8] Smith R.S., 1991. The macrophage theory of depression. *Medical Hypotheses*, 35 (4): 298-306.
- [9] Holsboer F., 2001. Prospects for antidepressant drug discovery. *Biological Psychology*, 57 (1-3): 47- 65.
- [10] Frih H., Sahraoui L., Frih N., Toumi L., Bairi A.M., Tahraoui A., Maurel D. & Siaud P., 2009. Facteurs prédictifs de la survenue du stress post traumatique chez des individus ayant vécu deux évènements de vie majeurs (tremblement de terre et terrorisme en Algérie): Réponse corticotrope et prolactinique à une faible dose de Dexaméthasone (0.5mg). *Evol. Psychiatr.*, 74: 581-591.
- [11] Holsboer F., 2000. The corticosteroid receptor hypothesis of depression. *Neuropsychopharmacology*, 23 (5): 477- 501.
- [12] Murphy B.E.P., Dhar V., Ghadirian A.M., Chouinard G. & Keller R., 1991. Response to steroid suppression in major depression resistant to antidepressant therapy. *Journal of Clinical Psychopharmacology*, 11 (2): 121-126.
- [13] Wolkowitz O.M., Reus V.I., Manfredi F., Ingbar J., Brizendine L. & Weingartner H., 1993. Ketoconazole administration in hypercortisolaemic patients. *American Journal of Psychiatry*, 150 (5): 810-812.
- [14] Kinobe R.T., Dercho R.A., Vlahakis J.Z., Brien J.F., Szarek W.A. & Nakatsu K., 2006. Inhibition of the enzymatic activity of heme oxygenases by azole-based antifungal drugs. *Journal of Pharmacology and Experimental Therapeutics*, 319 (1):277-84.
- [15] Frih H., Ali Rachedi B., Djenidi R., Frih N., Tahraoui A. & Bairi A.M., 2010. Le Ketoconazole antagonise les effets immuno-gonadotropes au test de la nage forcée chez le rat mâle Wistar. *Canadian journal of Physiology and Pharmacology*, 88: 733-744.
- [16] Pont A., 1987. Long-term experience with high-dose ketoconazole therapy in patients with stage D2 prostatic carcinoma. *Journal of Urology*, 137 (5): 902-904.
- [17] English H.F., Santner S.J., Levine H.B. & Santen R.J., 1986. Inhibition of testosterone production with ketoconazole alone and in combination with a gonadotropin releasing hormone analogue in the rat. *Cancer Research*, 46 (1): 38-42.
- [18] Adams M.L., Meyer E. & Cicero T.J., 1998. Imidazoles suppress rat testosterone secretion and testicular interstitial fluid formation *in vivo*. *Biology of Reproduction*, 59 (2): 248-254.
- [19] Santen R.J., Van den Bossche H., Symoens J., Brugmans J. & DeCoster R., 1983. Site of action of low dose ketoconazole on androgen biosynthesis in men. *Journal of Clinical Endocrinology and Metabolism*, 57: 732-736.
- [20] Marwaha R.K. & Maheshwari A., 1999. Systemic antifungal therapy in pediatric. *Indian Pediatrics*, 36 (10):1011-1021.
- [21] Munck A., Naray-Fejes-Toth A., Guyre P.M., 1987. Mechanism of glucocorticoid actions on the immune system. In: *Hormones and Immunity*, Ed. I. Berczi and K. Kovacs, 20-37.
- [22] Ishiyama N., Kitagawa M., Takahashi H., Kina T. & Hirokawa K., 1998. Expression of truncated VCAM-1 in lymphocytes and its role during the process of apoptosis. *Pathobiology*, 66 (6): 274-283.
- [23] Hirokawa K., Sato K. & Makinodan T., 1982. Influence of age of thymic graft on the differentiation of T cells in nude mice. *Clinical*

- Immunology and Immunopathology*, 24 (2): 251–262.
- [24] Kruger T.E., Smith L.R., Harbour D.V. & Blalock J.E., 1989. Thyrotropin: an endogenous regulator of the *in vitro* immune response. *Journal of Immunology*, 142 (3): 744–747.
- [25] Arzt E., Buric R., Stelzer G., Stalla J., Renner U. & Stalla G.K., 1993. Interleukin involvement in anterior pituitary cell growth regulation: effects of IL-2 and IL-6. *Endocrinology*, 132 (1): 459–467.
- [26] Karanth S., Lyson K. & McCann S.M., 1993. Role of nitric oxide in interleukin 2-induced corticotropin releasing factor release from incubated hypothalami. *Proceedings of the National Academy of Sciences*, 90 (8): 3383–3387.
- [27] Lambert A., Mitchell R. & Robertson W.R., 1986. The effect of Ketoconazole on adrenal and testicular steroidogenesis *in vitro*. *Biochem Pharmacology*, 355 (22): 3999–4004.
- [28] Grossman C.J., 1985. Interaction between the gonadal steroids and the immune system. *Science*, 227 (4684): 257–261.
- [29] Brunelli R., Frasca D., Fattorossi A., Spano M., Baschieri S., D'Amelio R., Zichela L. & Doria, G., 1991. Thymus regeneration induced by gonadectomy in old mice. Characterization of T cell phenotype and mitotic responsiveness. *Journal of Immunology Research*, 3: 62–68.
- [30] Greenstein B.D., Fitzpatrick F.T.A., Adcock I.M., Kendall M.D. & Wheeler M.J., 1986. Reappearance of the thymus in old rats after orchidectomy: Inhibition of regeneration by testosterone. *Journal of Endocrinology*, 110 (3): 417–422.
- [31] Utsuyama M., Hirokawa K., Mancini C., Brunelli R., Leter G. & Doria G., 1995. Differential effects of gonadectomy on thymic stromal cells in promoting T cell differentiation in mice. *Mechanisms of Ageing and Development*, 81 (2-3):107–117.
- [32] Utsuyama M. & Hirokawa K., 1989. Hypertrophy of the thymus and restoration of immune functions in mice rats by gonadectomy. *Mechanisms of Ageing and Development*, 47 (3):175–185.
- [33] Smagin G.N. & Goeders N.E., 2004. Effects of acute and chronic ketoconazole administration on hypothalamo–pituitary–adrenal axis activity and brain corticotropin-releasing hormone. *Psychoneuroendocrinology*, 29:1223–1228.
- [34] Deuschle M., Lecei O., Stalla G.K., Landgraf R., Hamann B., Lederbogen F., Uhr M., Luppa P., Maras, A., Colla M. & Heuser I., 2003. Steroid synthesis inhibition with ketoconazole and its effect upon the regulation of the hypothalamus–pituitary–adrenal system in healthy humans. *Neuropsychopharmacology*, 28 (2): 379–383.
- [35] MacAdams M.R., White R.H. & Chipps B.E., 1986. Reduction in serum testosterone levels during chronic glucocorticoid therapy. *Annals of Internal Medicine*, 140 (5): 648–651.
- [36] Rabin D., Gold P.W., Margioris A. & Chrousos G.P., 1988. Stress and reproduction: Interactions between the stress and reproductive axis. In: () Mechanisms of physical and emotional stress. Eds. G.P. Chrousos, D.L. Loriaux, P.W. Gold *Plenum Press, New York*. 377–390.
- [37] Rivier C., Rivier J. & Vale W., 1986. Stress-induced inhibition of reproductive function: Role of endogenous corticotropin releasing factor. *Science*, 231 (4738): 607–609.
- [38] Chrousos G.P., Torpy D.J. & Gold P.W., 1998. Interactions between the hypothalamic pituitary adrenal axis and the female reproductive system: Clinical implications. *Annals of Internal Medicine*, 129 (3):229–240.
- [39] Rivier C. & Rivest S., 1991. Effect of stress on the activity of the hypothalamic-pituitary-gonadal axis: Peripheral and central mechanisms. *Biology of Reproduction*, 45 (4): 523–532.
- [40] Tsigos C., Papanicolaou D.A., Kyrou I., Raptis S.A. & Chrousos G.P., 1999. Dose-dependent effects of recombinant human interleukin-6 on the pituitary-testicular axis. *Journal of Interferon Cytokine Research*, 19 (11): 1271–1276.