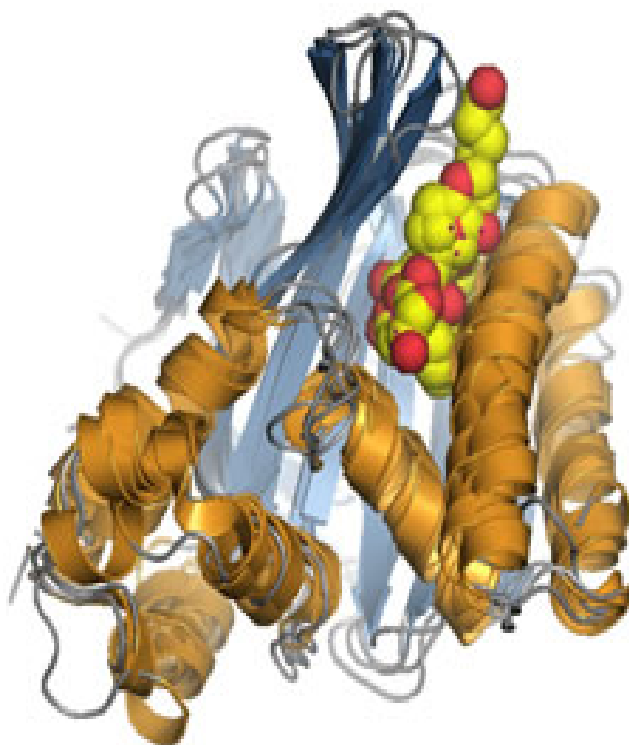


# PhytoChem & BioSub Journal

Peer-reviewed research journal on Phytochemistry & Bioactives Substances

ISSN 2170 - 1768



## PCBS Journal

Volume 8 N° 1, 2 & 3

2014

# PhytoChem & BioSub Journal

Peer-reviewed research journal on Phytochemistry & Bioactives Substances

ISSN 2170 - 1768

## PCBS Journal

*PCBS  
Journal*

Volume 8 N° 1

2014



Edition LPSO  
Phytochemistry & Organic Synthesis Laboratory  
<http://www.pcbsj.webs.com> , Email: phytochem07@yahoo.fr

## AN OVERVIEW ON AGE RELATED MACULAR DEGENERATION AND RECENT ADVANCES IN ITS MANAGEMENT

SOBIA NOOR\*, SARA FATIMA & AYESHA FATIMA

<sup>1</sup>Pharm.D, Department of Hospital and Clinical Pharmacy Practice, Deccan School Of Pharmacy, Hyderabad, A.P India.

Received: January 31, 2014; Accepted: April 04, 2014

Corresponding author Email: [sobianoor76@yahoo.com](mailto:sobianoor76@yahoo.com)

Copyright © 2014-POSL

DOI:10.163.pcbjsj/2014.8.1.12

**Abstract.** Age-related macular degeneration (AMD) is a condition characterized, in the early stages, by slow development and progression, absence of symptoms over a number of years, and extensive retinal deposits called drusen, often associated with pigmentary abnormalities (early AMD). There is strong and consistent evidence that increasing age, family history, obesity/high body mass index, and cataract surgery are associated with late AMD. Smoking is the strongest and most consistently found modifiable risk factor for late AMD. Age-related macular degeneration remains one of the most severe and profound disabilities encountered in medicine, particularly due to the loss of the central vision and the high economic burden it places on patients and societies. Recent advances in management of AMD is anti-angiogenic drugs. The identification of the crucial role played by vascular endothelial growth factor (VEGF) in the pathogenesis of wet AMD has allowed the development of VEGF-blocking agents such as bevacizumab, pegaptanib and ranibizumab.

**Key Words:** age-related macular degeneration, smoking, vascular endothelial growth factor, bevacizumab, pegaptanib, ranibizumab

### LIST OF ABBREVIATIONS

**AMD:** Age-related macular degeneration

**CFH:** Complement factor H

**OCT:** Ocular coherence tomography

**RPE:** Retinal pigment endothelium

**ARM:** Age-related maculopathy

**CNV:** Wet AMD

**PDT:** Photodynamic therapy

**VEGF:** Vascular endothelial growth factor

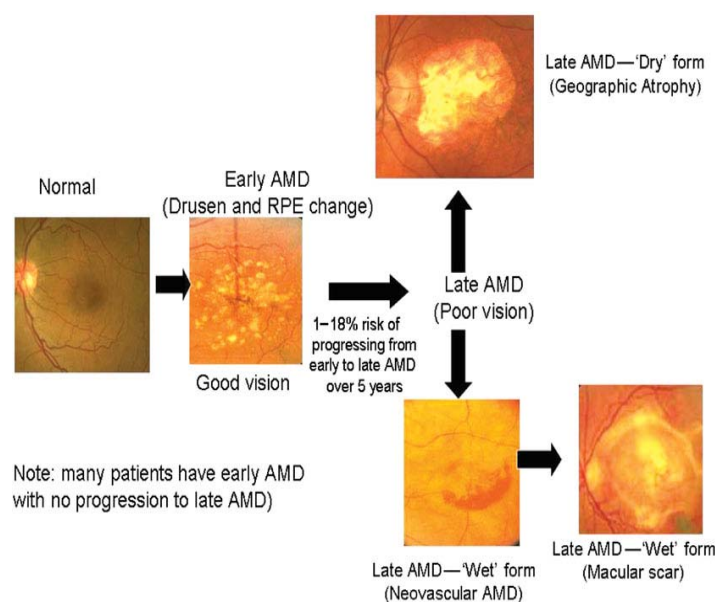
### Introduction

Age-related macular degeneration is the most frequent cause of severe vision loss in persons older than 50 years in the western world.<sup>1</sup>

Age-related macular degeneration (AMD) remains one of the most severe and profound disabilities encountered in medicine, particularly due to the loss of the central vision and the high economic burden it places on patients and societies.<sup>2</sup>

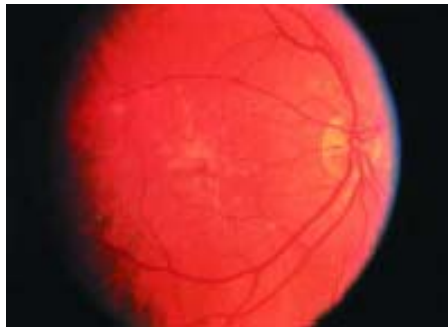Age-related macular degeneration (AMD) is a condition characterized, in the early stages, by slow development and progression, absence of symptoms over a number of years, and extensive retinal deposits called drusen, often associated with pigmentary abnormalities (early AMD). The advanced presentation of AMD also includes geographic atrophy and choroidal neovascularization. The patient complains of metamorphopsia, discromatopsia, vision loss, and central scotoma.<sup>3</sup> AMD is a disease with progressive, painless loss of central vision associated with ageing. AMD is widely classified into 'dry' and 'wet' types. 'Dry' AMD accounts for 10% of patients with visual loss and can be further classified into early, intermediate and late stages characterized by the presence of hyper and/or hypo-pigmentation with drusen within the macula. Studies have shown that drusen size is an important risk factor for predicting risk of advanced AMD. Large drusen are defined as those (within 2 standard disc diameters of the centre of the macula) with (shortest) diameter greater than or equal to that of an average normal retinal vein at the disc margin, considered to be approximately one-twelfth disc diameter or approximately 125  $\mu\text{m}$ , when the average disc diameter is taken as 1500  $\mu\text{m}$ ; intermediate drusen are those with a disc diameter greater than or equal to one-half that of large drusen (63  $\mu\text{m}$ ). Drusen are extracellular deposits that accumulate between the basal lamina of the retinal pigment epithelium (RPE) and the inner collagenous layer of Bruch's membrane in the human eye. They are typically associated with advancing age and are commonly observed in a variety of chorioretinal pathologies, including age-related macular degeneration. It is believed that local chronic inflammation through the activation of the alternative complement pathway with enucleation of drusen core. The consequent expansion affects the retinal pigment epithelium resulting in advancement from early to late stages. Late 'dry' AMD (geographical atrophy) and 'wet' AMD (choroidal neovascularization) are both classified as advanced AMD. Diagnosis and management of both these types of conditions differ.<sup>4</sup>

## Classification



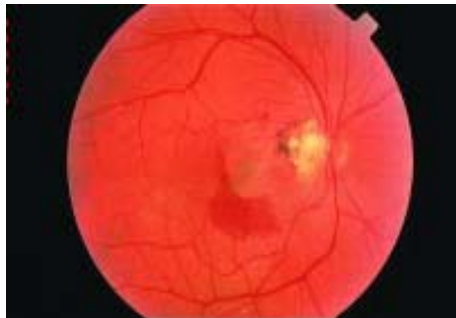**Figure 1**

Age-related macular degeneration is typically classified into two clinical forms, non-exudative or “dry” and exudative or “wet”, both of which can lead to visual loss. In the dry or non-exudative form, visual loss is usually gradual. The hallmark changes that are seen in the macula are yellow subretinal deposits called drusen, or retinal pigment epithelium (RPE) hyperpigmentary or hypopigmentary irregularities (Fig2). Drusen may enlarge and become confluent, and even evolve into drusenoid RPE detachments, where the RPE becomes separated from its underlying Bruch’s membrane. These drusenoid detachments often progress to geographic atrophy, where the RPE dies from apoptosis or into wet AMD.



**Figure 2** Numerous soft drusen are noted to coalesce beneath the retina in the macula.

In the wet form, also called exudative or neovascular AMD, vision loss can occur suddenly when a choroidal neovascular membrane (Fig3) develops in the sub-RPE, between the RPE and Bruch’s membrane, and it subretinal space, between the neurosensory retina and RPE, and it leaks fluid or blood.<sup>5</sup>



**Figure 3:** A choroidal neovascular membrane with subretinal hemorrhage and lipid exudates.

Common symptoms of age-related macular degeneration<sup>6</sup>

- Decreased visual acuity
- Metamorphopsia
- Blurred visual acuity
- Dark spot in the visual field (scotoma)
- Foggy vision/haze
- Difficulty reading
- Floaters



- Sparks or flashes (photopsia)

**Risk factors:**

Although the etiology of AMD is not completely understood, large numbers of risk factors have been reported. From the disease management point of view, risk factors are classified as either un-modifiable or modifiable. There is strong and consistent evidence that increasing age, family history, obesity/high body mass index, and cataract surgery are associated with late AMD. Smoking is the strongest and most consistently found modifiable risk factor for late AMD.<sup>7</sup>

A systematic review identified 18 prospective and cross-sectional studies and 6 case control studies involving 113,780 persons with 17,236 cases of late AMD that included an estimate of the association between late AMD and at least one of 16 pre-selected risk factors. Increasing age, current cigarette smoking, previous cataract surgery, and a family history of AMD showed strong and consistent associations with late AMD. Risk factors with moderate and consistent associations were higher body mass index, history of cardiovascular disease, hypertension, and higher plasma fibrinogen.<sup>8</sup>

A prospective study of self-reported clinically diagnosed macular degeneration in male and female runners followed prospectively for 7.7 years concluded that higher doses of vigorous exercise (running) was associated with lower incidence of AMD risk.<sup>9</sup>

The ALIENOR population-based study on age-related eye diseases in 963 residents of Bordeaux, France, aged 73 years or older conducted to explore the association of AMD with long-term average blood pressure (BP) parameters, including pulse pressure (PP) concluded that elderly patients with high SBP and high PP may be at increased risk for developing early or late AMD.<sup>10</sup>

A Population-based cohort study was conducted to examine the association between potential risk factors and the 14-year incidence of age-related maculopathy (ARM). The study indicated a direct correlation between age, cataract, family history, alcohol consumption, the apolipoproteins A1 and B and the 14-year incidence of ARM.<sup>11</sup>

**Epidemiology**

In developed countries AMD is a common cause of visual loss. Neovascular AMD accounts for more than 80% of AMD visual loss, but less than 15% develop neovascular AMD (< 1% of category 1 or 2 patients).<sup>12</sup>

The prevalence of AMD increases with age and is likely to rise as the population of those older than 65 years increases. Worldwide estimates indicate that by 2020 as many as 8 million persons older than 65 years could suffer from AMD.<sup>1</sup>

A study found that AMD occurs in patients over the age of 55 years. It also estimated that AMD affects .1.75 million individuals aged 40 years in the USA. Owing to the rapidly ageing population, this figure is projected to rise to almost 3 million by 2020. Furthermore, 10–15% of patients with AMD have severe loss of central vision. The prevalence of AMD varies between racial groups with higher prevalence in European-descended populations. Pooled data from three large epidemiological studies showed that drusen were strongly age-related in the black population, and that sight-threatening AMD was less prevalent than in a white population.<sup>13</sup>

**Pathophysiology**

The AMD is greatly influenced by genetic factors in the pathogenesis, and genetic mechanisms underlying this disease are complex. Researches have indicated a number of AMD-associated genes in mechanistic pathways related to DNA repair, complement system activation,

microglial recruitment, inflammation, neovascularization, and extracellular matrix function. In 2005, independent research groups across the United States published a breakthrough identifying a DNA sequence variant in complement factor H that is associated with AMD. They found that single nucleotide polymorphism corresponding to a tyrosine to histidine polymorphism at position 402 which profoundly raise the odds for developing AMD.<sup>2</sup>

In a multi-centered case-control study was conducted to show an association between age-related macular degeneration (AMD) and genetic variants of 10 genes in a nation wide Chinese population concluded that gene variants in CFH, ARMS2, and HTRA1 contribute to AMD in the Chinese population.<sup>14</sup>

Family history is a well-known risk factor for the development of AMD. For instance, twin studies found that the concordance rate for AMD in monozygotic twins was almost double that of dizygotic twins. Genetic studies identified the most important genetic factor to be the complement factor H (CFH) gene, a major inhibitor of the complement system. A common coding variant of this gene significantly increases the risk for AMD and very likely explains approximately 43% of AMD in older adults. Thus, the genetic factor alone may be the decisive factor in determining disease prevalence in any given ethnic group.<sup>15</sup>

### Diagnosis

Patients with early 'dry' AMD are usually asymptomatic which may progress to blurring of vision and loss of central vision. Patients with 'wet' AMD usually report a sudden deterioration in vision which may be associated with distortion of the image, due to the fluid and haemorrhage build-up in the subretinal space. This can be further tested with an Amsler grid. If 'wet' AMD is suspected, fluorescein angiography and ocular coherence tomography (OCT) based on laser interferometry is used to investigate and confirm this. By identifying intraretinal, subretinal or sub-RPE fluid, OCT helps identify the type of neovascular AMD.<sup>4</sup>

Ophthalmoscopy is used to diagnose the condition. CNV can be identified by the presence of fluorescein dye within the neovascular tissue using intravenous fluorescein angiography.<sup>16</sup>

### Management

There is no specific treatment for dry AMD, but patients should be offered advice on cessation of smoking, the importance of a healthy diet including plenty of fruits and vegetables, the avoidance of ultraviolet and blue light and the potential value of nutritional supplements for prevention of progression to advanced AMD.

Low vision aids are useful in treating early 'dry' type AMD but once early 'dry' AMD reaches the advanced stage, no form of treatment can prevent vision loss. Treatment and monitoring can delay and possibly prevent intermediate 'dry' AMD from progressing to advanced AMD.<sup>4</sup>

A systematic review and meta-analysis was conducted to evaluate the effectiveness of dietary antioxidants in the primary prevention of age related macular degeneration (AMD) concluded that there is insufficient evidence to support the role of dietary antioxidants, including the use of dietary antioxidant supplements, for the primary prevention of early AMD.<sup>17</sup>

The Age-Related Eye Disease Study (AREDS) demonstrated that 5 years of supplementation with high doses of antioxidant vitamins (A, C and E) and zinc reduced the risk of developing advanced AMD by about 25% in the contralateral eye of subjects with pre-existing moderate to advanced dry or wet AMD in one (the study) eye. Wet AMD (CNV) represents only 10% of the overall disease prevalence, but is responsible for 90% of the cases for severe visual loss. Treatment for CNV will therefore have maximum impact on reducing the burden of severe visual

loss due to this condition. There have been significant advances in the treatment opportunities for wet AMD recently. Studies on treatments for CNV have reported their findings using logMAR visual acuity charts, which have five letters on each line and three lines representing a doubling of the visual angle. In other words, the difference between 6/6 and 6/12 Snellen acuity (and 6/12 and 6/24, etc.) is three lines of logMAR acuity or 15 letters. Moderate and severe visual loss is described as the loss of three and six lines of logMAR acuity, respectively. Argon laser photocoagulation has been used since the 1970s to treat CNV. The aim is to destroy the neovascular membrane by coagulation, but such treatment also destroys the overlying retina, with a resultant scotoma. For this reason, subfoveal and juxtafoveal CNV are rarely treated by laser photocoagulation, as there is usually an immediate post-treatment reduction in central vision. Well defined, extrafoveal CNV can be treated by photocoagulation, with reduction in severe visual loss; however, such lesions represent only 8% of all CNV at presentation, and long-term results are limited by high recurrence rates (54% at 5 years).<sup>18</sup>

Photodynamic therapy has been recommended by the National Institute for Clinical Excellence (NICE) for the treatment of predominantly 'classic' wet ARMD in patients with visual acuities no worse than 6/60: verteporfin is injected intravenously, binds to the subretinal neovascular membrane, and is laser activated, which releases destructive free radicals and results in significantly reduced visual loss progression. There are an estimated 7000 patients eligible for treatment with verteporfin based on the NICE criteria, which has recently been broadened in some primary care trusts. Photodynamic therapy focuses on the membrane rather than the underlying angiogenic molecular environment, so there is reduction in efficacy over time.<sup>19</sup>

A systematic review of two RCTs, the Treatment of AMD with Photodynamic therapy (TAP) Study and Verteporfin in Photodynamic Therapy (VIP) Study, found that PDT with Verteporfin significantly reduced the risk of moderate and severe visual loss at 24 months compared with placebo (moderate visual loss: OR, 0.77; severe visual loss: OR, 0.62) in eyes with subfoveal CNV measuring 5400  $\mu\text{m}^2$  caused by AMD. Two-year follow-up data showed that 77% of eyes with 100% classic lesions lost less than 15 letters after PDT treatment compared with 31% in the placebo group. Two-year follow-up data for predominantly classic lesions showed 59% of eyes lost less than 15 letters of visual acuity compared with 31% of the placebo group. Patients with 100% occult lesions respond relatively well to PDT treatment (51% of treated patients lost 15 letters versus 25% controls at 2 years). A controversial sub-group analysis found maximal benefit in smaller lesions and those with poor initial vision. Patients with minimally classic lesions or occult classic CNV were not shown to benefit from PDT in randomized trials.<sup>13</sup>

Interventional research has centred on wet ARMD and anti-angiogenesis either through direct obliteration of neovascular membranes or inhibition of pro-angiogenic cytokines, such as vascular endothelial growth factor (VEGF).<sup>19</sup>

### **Anti-angiogenic drugs**

There is currently extensive research into modulating the angiogenic response in AMD. There is extensive *in vitro* and *in vivo* evidence that VEGF is implicated in retinal angiogenesis and vascular permeability. There has been intense laboratory and clinical research in this area, and researchers have developed agents that block VEGF activity some of which are already in clinical use.<sup>13</sup>

The identification of the crucial role played by vascular endothelial growth factor (VEGF) in the pathogenesis of wet AMD has allowed the development of VEGF-blocking agents such as bevacizumab (Avastin), pegaptanib (Macugen) and ranibizumab (Lucentis). This is the first



generation of drugs which start to control the vision loss from late disease in all types of wet AMD and, in some cases, to produce improvement. Macugen was shown to be more effective than PDT in treating wet AMD and to reduce the probability of developing severe vision loss (by about 50% over one year). However, like PDT, it only delayed vision loss but did not prevent it. Subsequently, it was shown that Lucentis was more effective than Macugen and could prevent further vision loss: about 95% of patients maintained their baseline vision whilst on treatment. Furthermore, one third of patients experienced a gain of vision (more than 15 letters of visual acuity). In 2005, it was demonstrated that Avastin, the molecule from which Lucentis is derived, could also be used for the treatment of wet AMD, although this was not its original use. Since then, the use of Avastin for the treatment of AMD has been widely reported; the literature suggests that its efficacy is similar to that of Lucentis, as well as its toxicity. The advantages of Avastin are a lower cost and longer half-life (allowing for six-weekly dosing, rather than four weekly as for Lucentis).<sup>20</sup>

The efficacy and safety of ranibizumab in neovascular AMD has been demonstrated in the ANCHOR and MARINA trials. Further studies including the PIER, PrONTO, and SUSTAIN trials have also evaluated the optimal dosing regimen of ranibizumab in neovascular AMD. The CATT and IVAN trials compared the safety and efficacy of ranibizumab with off-label use of bevacizumab. Studies such as SUSTAIN and HORIZON have shown that ranibizumab has a good safety profile and is well tolerated for over 4 years with very few serious ocular and systemic adverse events. For DME, Phase II RESOLVE study and Phase III RISE and RIDE studies have demonstrated superiority of ranibizumab treatment in improving vision over placebo controls. Phase II READ and Phase III RESOLVE and REVEAL studies have shown that ranibizumab is more effective both as monotherapy and in combination with laser compared with laser monotherapy. The 3-year results from the DRCR net protocol I study found that ranibizumab with deferred laser resulted in better long-term visual outcome compared with ranibizumab with prompt laser.<sup>21</sup>

Two concurrent, prospective, randomized, double-blind, multicenter, dose-ranging, controlled clinical trials using broad entry criteria were conducted. Pegaptanib, an anti-vascular endothelial growth factor therapy, was evaluated in the treatment of neovascular age-related macular degeneration. Intravitreal injection into one eye per patient of pegaptanib (at a dose of 0.3 mg, 1.0 mg, or 3.0 mg) or sham injections were administered every 6 weeks over a period of 48 weeks. The primary end point was the proportion of patients who had lost fewer than 15 letters of visual acuity at 54 weeks. The study concluded that Pegaptanib appears to be an effective therapy for neovascular age-related macular degeneration.<sup>22</sup>

## Conclusion

Age related macular degeneration (AMD) is the leading cause of visual impairment in the Western world and represents a substantial and growing healthcare burden. AMD causes a number of impairments including deteriorating visual acuity, central visual field sensitivity, and contrast sensitivity. These impairments usually cause significant disability, with difficulties with reading, everyday activities of daily living, watching television, all of which may impact on quality of life. Advances in treatment of AMD, VEGF-blocking agents shown to be more effective than PDT in treating wet AMD and to reduce the probability of developing severe vision loss (by about 50% over one year). However, like PDT, it only delayed vision loss but did not prevent it.

## References

1. Neil M. Bressler, et al. Early Detection and Treatment of Neovascular Age-related Macular Degeneration, *JABFP* March–April 2002 Vol. 15 No. 2;142-152.
2. Kang Liu, Bolin Xie et al. Today and Future of Age-Related Macular Degeneration, *International Scholarly Research Network (ISRN) Ophthalmology* Volume 2012.
3. Giuseppe Querques et al. Age-related macular degeneration, *Clinical Ophthalmology* 2011;5 593–601.
4. Tariq Ayoub, Nishal Patel et al. Age-related macular degeneration, *J R Soc Med* 2009 102: 56-61.
5. Marianne L. Shahsuvaryan et al. Age-Related Macular Degeneration: Alternative Therapy, *Journal of Pharmacy and Alternative Medicine* 2013, Vol. 2, No. 1,14-22.
6. Darius M. Moshfeghi et al. Age-related macular degeneration: Evaluation and treatment, *Cleveland Clinic Journal of Medicine* December 2003 volume 70 • number 12 1017-1037.
7. Lei Liu et al. Improving patient outcomes: role of the primary care optometrist in the early diagnosis and management of age-related macular degeneration, *Clinical Optometry* 2013;5 112.
8. Usha Chakravarthy et al. Clinical risk factors for age-related macular degeneration: a systematic review and meta-analysis, *BMC Ophthalmology* 2010, 10:31.
9. Paul T. Williams et al. Prospective Study of Incident Age-Related Macular Degeneration in Relation to Vigorous Physical Activity during a 7-Year Follow-up, *IOVS*, January 2009, Vol. 50, No. 1;101-106.
10. Cecile Delcourt et al. Long-Term Blood Pressure and Age-Related Macular Degeneration: The ALIENOR Study, *Vis Sci.* 2013;54:1905–1912.
11. Helena Buch et al. Risk factors for age-related maculopathy in a 14-year followup study: the Copenhagen City Eye Study, *Acta Ophthalmol. Scand.* 2005: 83: 409–418.
12. Michael R. Kolber et al. Vitamins for age-related macular degeneration demonstrate minimal differences, *Canadian Family Physician* 2013 Vol 59: MAY,503.
13. A. Tufail et al. Age-related macular degeneration: diagnosis and management, *British Medical Bulletin* 2008; 85: 127–149.
14. Xiaoxin Li et al. Association of Genetic Polymorphisms and Age-Related Macular Degeneration in Chinese Population, *Invest Ophthalmol Vis Sci.* 2012;53: 4262–4269.
15. Michael Waisbourd et al. About Genetics, Lifestyle and Age-Related Macular Degeneration, *IMAJ* 2007;9:674–675.
16. Erica Weir et al. Age-related macular degeneration: armed against ARMD, *CMAJ* 2004; 170 (4); 463-464.
17. Tien Y Wong et al. Dietary antioxidants and primary prevention of age related macular degeneration: systematic review and meta-analysis, *BMJ* 2007; doi:10.1136/bmj.39350.500428.47.
18. Fraser R. Imrie et al. New treatments for age-related macular Degeneration, *Age and Ageing* 2007; 36: 8–10.
19. Ameenat Lola Solebo et al. Recent advances in the treatment of age-related macular degeneration, *British Journal of General Practice*, May 2008;309-310.
20. Lyndon da Cruz et al. New developments in age-related macular degeneration, *AMD update* 2008.
21. Timothy YY Lai et al. Long-term effectiveness of ranibizumab for age-related macular degeneration and diabetic macular edema, *Clinical Interventions in Aging* 2013;8 467–483.
22. Evangelos S. Gragoudas et al. Pegaptanib for Neovascular Age-Related Macular Degeneration, *n engl j med* 2004;351;27:2805-2816.

# PhytoChem & BioSub Journal

Peer-reviewed research journal on Phytochemistry & Bioactives Substances

ISSN 2170 - 1768



*PCBS  
Journal*



Edition LPSO

Phytochemistry & Organic Synthesis Laboratory  
<http://www.pcbsj.webs.com> , Email: phytochem07@yahoo.fr